



# Is Surgery of Atypical Carcinoid Possible During Active Pulmonary Tuberculosis?

Lora Novaković Lacković,<sup>1,2</sup> Sonja Ukmar,<sup>2</sup> Mladen Duronjić,<sup>2</sup> Milica Srećić Tomić,<sup>2</sup> Marko Kantar<sup>3</sup>

## Abstract

Atypical lung carcinoids are rare compared to other lung cancers and are classified as tumours of medium malignancy. Pulmonary tuberculosis is the second leading cause of death from infectious diseases. The paper presents the case of a 46-year-old female patient who was surgically treated during acute tuberculosis. The patient recovered and is under the supervision of a pulmonologist oncologist.

**Key words:** Cough; Carcinoid tumour; Tuberculosis; Pulmonary.

1. Faculty of Medicine, University of Banja Luka, Banja Luka, The Republic of Srpska, Bosnia and Herzegovina.
2. Clinic for Pulmonary Diseases, University Clinical Centre of the Republic of Srpska, Banja Luka, The Republic of Srpska, Bosnia and Herzegovina.
3. Department of Thoracic Surgery, University Clinical Centre of the Republic of Srpska, Banja Luka, The Republic of Srpska, Bosnia and Herzegovina.

### Citation:

Novaković Lacković L, Ukmar S, Duronjić M, Srećić Tomić M, Kantar M. Is surgery of atypical carcinoid possible during active pulmonary tuberculosis? Scr Med. 2024 May-Jun;55(3):391-5.

### Corresponding author:

LORA NOVAKOVIĆ LACKOVIĆ  
T: +387 51 343 209  
E: lora.novakovic@kc-bl.com

Received: 30 March 2024  
Revision received: 9 May 2024  
Accepted: 9 May 2024

## Introduction

Carcinoid tumours constitute a mere 2 % of the total incidence of pulmonary tumours, originating from Kulchitsky cells, which are stem cells located within the bronchial epithelium exhibiting neuroendocrine differentiation.<sup>1</sup> Atypical carcinoid (AC) tumours, with a frequency of merely 0.2 %, are less prevalent compared to their typical counterparts. These atypical variants are distinguished by an augmented mitotic count (exceeding 2 per 2 mm<sup>2</sup>), presence of punctate necrosis and an enhanced propensity for metastatic spread.<sup>2</sup> Diagnostic confirmation of carcinoid tumours *via* immunohistochemical staining is achieved using markers such as chromogranin A, synaptophysin, CD56 and TTF-1.<sup>3</sup> Approximately 80 % of AC tumours exhibit a cen-

tral location within the pulmonary architecture and demonstrate no association with smoking. Therapy of choice is surgical intervention, which typically involves complete resection, including lobectomy and segmentectomy.<sup>4</sup>

In the realm of infectious diseases, pulmonary tuberculosis (TB) ranks as the second cause of mortality after COVID-19, with a reported prevalence of 10.6 million individuals in 2022. This figure represents a 4.5 % increase since 2020, including a 3.5 % rise in new cases.<sup>5</sup> TB is prevalent in all countries and across all age groups. It is critical to emphasise that pulmonary TB can be effectively prevented through vaccination and successfully treated with antibiotic therapy.

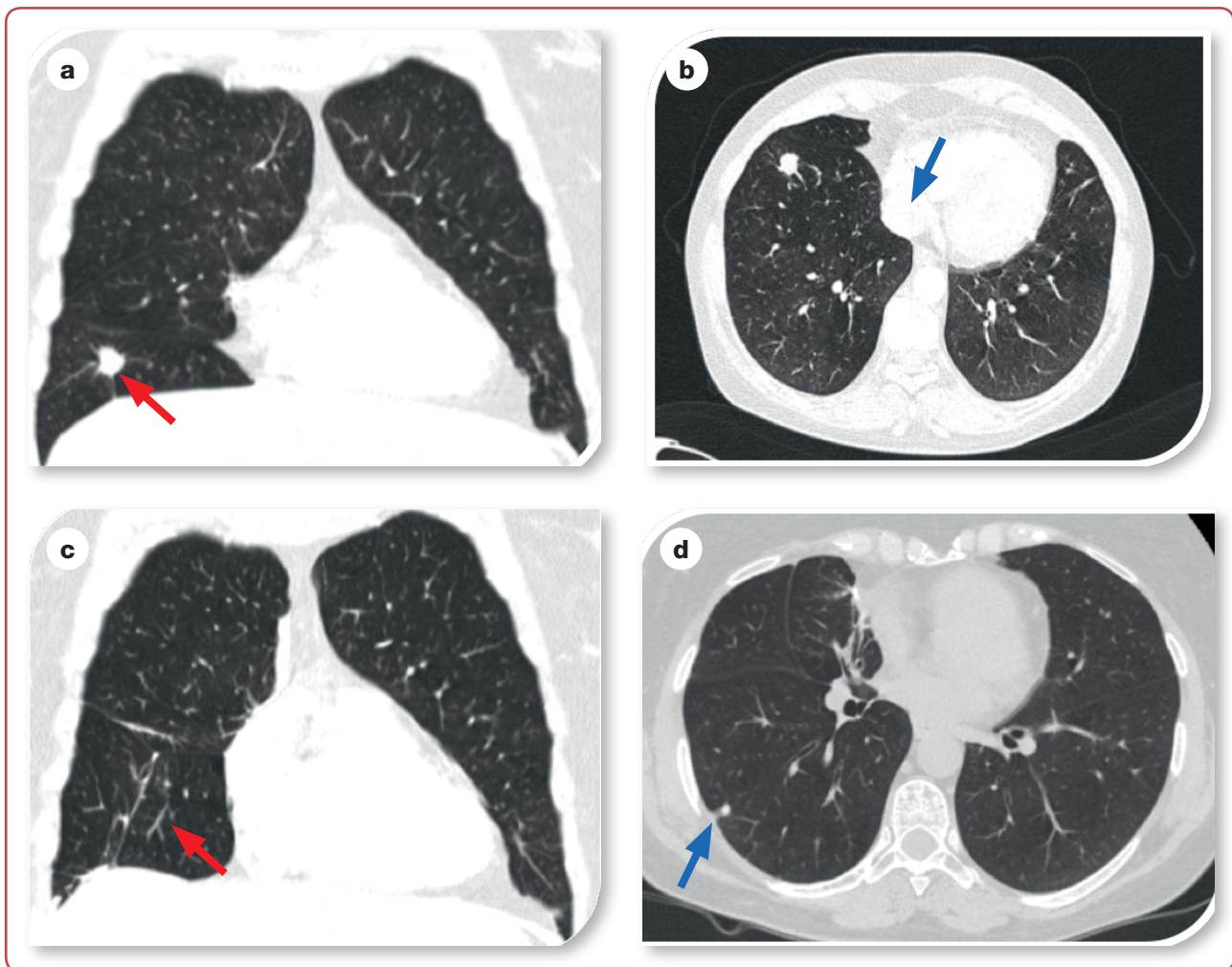
## Case history

In November 2022, a 46-year-old female patient underwent a computed tomography scan of the chest. Patient had a persistent cough lasting approximately one year. This radiological examination described pathological alterations in middle and lower lobes of right lung: neoplastic lesion with spiculated margins, measuring 14 x 12 x 16 mm (Figure 1a, red arrow). This lesion, exhibiting pleural retraction, was predominantly localised within the inferior lobe. Additionally, a distinct solid lesion was detected in the right middle lobe, in close proximity to the pericardium. Characterised by adjacent adhesions, this lesion was diagnostically classified as post-inflammatory (Figure 1b, blue arrow). The female patient with a 20-year history of tobacco use had a multifaceted medical history, including bronchial asthma (di-

agnosed in 2017), ulcerative colitis (diagnosed in 2006), hypothyroidism (diagnosed in 2020) and sideropenic anaemia.

The current pharmacological regimen included inhaled corticosteroids combined with long-acting  $\beta$ -agonists (ICS + LABA), mesalazine in both tablet and suppository forms and systemic corticosteroids administered during exacerbations of ulcerative colitis. Additionally, the therapeutic protocol incorporated levothyroxine for thyroid insufficiency and iron supplements to address the anaemic condition. Clinically, the patient reported experiencing fatigue under conditions of heightened physical stress.

Pulmonary function assessment *via* spirometry



**Figure 1:** Contrast-enhanced CT image of the chest showing: a) tumour in the right lung's lower lobe with spiculated margins, measuring 14x12x16 mm (red arrow) that retracts the pleura; b) solid lesion in the right middle lobe, in close proximity to the pericardium with adjacent adhesions (blue arrow); c) fibrotic alterations in the right lower lobe after surgery (red arrow); d) subpleural nodule measuring less than one cm in segment S6 of the right lung after surgery (blue arrow).

revealed a mild obstructive ventilatory impairment, quantified by the following parameters: vital capacity (VC) at 81 %, forced expiratory volume in the first second (FEV1) at 82 %, Tiffeneau-Pinelli Index at 58 % and maximal expiratory flow at 50 % of lung volume (MEF50) at 23 %. Upon bronchoscopic examination, normal endoscopic findings were observed, prompting the thoracic surgeon to recommend video-assisted thoracoscopic surgery (VATS) with intraoperative extemporaneous histopathological assessment. In November 2022, the patient underwent uniportal video-assisted thoracoscopic surgery (UVATS), encompassing an atypical resection of the right lung's lower lobe (histologically confirmed as benign *ex tempore*) and an atypical resection of the right lung's middle lobe.

Pathohistological analysis post-surgery characterised the lesion in the lower lobe as granulomatous inflammation accompanied by caseous necrosis. Microscopic examination revealed lung tissue interspersed with granulation tissue and granulomas, comprising epithelioid cells, lymphocytes and multinucleated giant cells of the Langhans type, along with foreign body-type giant cells. The lesion in the middle lobe was defined as an AC tumour, staged pT1aNxL+VOPN0. Immunohistochemical staining yielded positive results for synaptophysin, chromogranin and TTF-1, along with moderate positivity for CK7 and Ki-67, the latter exhibiting nuclear positivity in approximately 5 % of cells and was negative for p40. Following the establishment of malignancy and the acquisition of definitive pathohistological evidence, the thoracic surgical team recommended conducting a lobectomy of the middle lobe coupled with lymphadenectomy.

However, the preoperative strategy was modified due to pathohistological confirmation of TB. This necessitated the initiation of anti-TB therapy, spanning a duration of 6-8 weeks, prior to the surgical intervention. The 4-drug regimen in tablet form (isoniazid, rifampicin, ethambutol and pyrazinamide), commenced in February 2023. After completing seven weeks of anti-TB treatment, a mediastinal lobectomy of the middle lobe, along with hilar and mediastinal lymphadenectomy, was performed in March 2023. Subsequent pathohistological analysis substantiated the diagnosis of an AC tumour, with no evidence of lymphatic metastasis (classified as pT2aN0). Post-operatively, the regimen of anti-TB therapy, comprising isoniazid and rifampicin, was sus-

tained until August 2023. A follow-up chest computed tomography scan conducted in September 2023 revealed the absence of oncological or TB recurrence. This imaging study described fibrotic alterations in the right lower lobe (Figure 1c, red arrow), alongside the identification of a subpleural nodule measuring less than one centimetre in segment S6 of the right lung (Figure 1d, blue arrow). Additionally, a standard positron emission tomography-computed tomography (PET-CT) scan performed within the same month did not depict any metabolic activity within the S6 nodule on the right side. Continuous surveillance of the patient's condition remains an ongoing process.

## Discussion

The cough reflex predominantly represents the primary symptomatic manifestation of pulmonary pathologies. A cough that persists more than three weeks may be indicative of an array of alternative health complications. The potential for concurrent lung diseases to be obscured warrants a heightened level of clinical vigilance. The main challenge encountered in the management of chronic cough lies within the precise etiological identification, as accurate diagnosis is imperative for the cessation of symptoms through targeted therapeutic interventions.

Within the categorisation of neuroendocrine neoplasms, AC are classified as neoplasms exhibiting intermediate malignant potential. These neoplasms are comparatively rare, constituting approximately 20 % of pulmonary carcinoids. Pulmonary carcinoids themselves account for a mere 1 % of all neoplastic formations within the United States.<sup>6</sup> Typically, these tumours are diminutive in size, with a central pulmonary localisation evident in 80 % of cases.<sup>7</sup> It is imperative to note that all pulmonary carcinoids are inherently malignant, possessing metastatic capabilities.<sup>8</sup> From a diagnostic perspective, the identification of AC tumours presents significant challenges, frequently due to their clinical presentation mimicking bronchial asthma, a phenomenon extensively documented in the scientific literature.<sup>9,10</sup> In the present case, the radiological manifestation of pulmonary TB deviates from the conventional pattern. Ordinarily, the primary site of TB is in the apical regions of the lungs. However, the detection of TB in the lower lobe, especially when

considering its radiographic profile, presented an unusual clinical scenario. Notably, it has been observed that in patients with comorbidity such as diabetes mellitus, TB frequently exhibits atypical radiographic characteristics. This variant, often impacting the middle and lower zones of the pulmonary field, is referred to as basal or lower lobe TB and may extend to hilar, parahilar and perihilar regions. Such atypical presentations underscore the complexity of TB pathology, particularly in the context of concurrent endocrine disorders.<sup>11</sup>

The concomitant diagnosis of pulmonary TB in patients slated for surgical intervention significantly increases both intraoperative and post-operative risks, predominantly attributed to the potential for dissemination and clinical exacerbation of TB. Optimal management often necessitates deferral of surgical procedures until the completion of anti-TB treatment. In scenarios where individuals with active TB require emergent surgical intervention, preoperative initiation of anti-TB therapy is imperative.<sup>12</sup> In such clinical cases, a carefully designed and long-term TB treatment strategy is needed. This approach requires close cooperation between the surgical team and pulmonologists.<sup>13</sup> It merits attention that a considerable number of cases documenting the concurrent occurrence of asthma and TB have been registered globally, with numerous scholarly inquiries endeavouring to elucidate their interrelation. Asthmatic patients exhibit an elevated susceptibility to pulmonary infections, attributable to the asthma-induced immune response, which culminates in hypertrophy and inflammatory cell infiltration of the respiratory tract mucosa. This pathological state fosters increased reactivity and bacterial colonisation.<sup>14</sup>

Historical records tracing the simultaneous presentation of TB and lung cancer date back to the 19th century. The correlation between TB and lung cancer has been extensively scrutinised in various scientific studies, yet the determination of whether this association is merely coincidental or possesses an etiological underpinning remains ambiguous.<sup>15</sup> The literature reveals a paucity of research exploring the triad of lung diseases – asthma, AC and TB. The predominant factors contributing to this scarcity are likely rooted in a generalised lack of clinical suspicion regarding disease coexistence, limitations in diagnostic acumen, or constraints in available diagnostic modalities.<sup>16</sup>

## Conclusion

This clinical case exemplifies the phenomenon of a rare pathology being obscured by a more prevalent condition. It underscores the imperative in all instances of chronic cough, irrespective of pre-existing diagnoses, to rigorously pursue an expansive differential diagnosis. Such approach is crucial in unveiling potentially underlying rare pathologies that might otherwise remain undetected in the shadow of more common diseases.

## Ethics

Access to her medical records was approved in writing by the patient and approved by the Ethics Committee of the University Clinical Centre of the Republic of Srpska (decision No 01-19-78-2/24, dated 20 March 2024).

## Acknowledgement

None.

## Conflicts of interest

The author declares that there is no conflict of interest.

## Funding

This research received no specific grant from any funding agency in the public, commercial, or not-for-profit sectors.

## Data access

The data that support the findings of this study are available from the corresponding author upon reasonable individual request.

## Author ORCID numbers

Lora Novaković Lacković (LNL):  
0000-0002-7588-1477  
Sonja Ukmar (SU):  
0009-0006-4233-2590  
Mladen Duronjić (MD):  
0009-0005-6686-0525  
Milica Srećić Tomić (MST):  
0009-0000-9857-1124  
Marko Kantar (MK):  
0009-0005-9405-9162

## Author contributions

Conceptualisation: LNL  
Resources: MD, MK  
Writing – original draft: SU  
Writing – review and editing: LNL  
Visualisation: MK, LNL  
Supervision: MST  
Project administration: LNL

## References

- Garg R, Kumar R, Singh P, Kshetrimayum S. Atypical carcinoid tumor of the lung: A rare entity. *Lung India.* 2019 May-Jun;36(3):236-8. doi: 10.4103/lungindia.lungindia\_111\_16.
- Arrigoni MG, Woolner LB, Bernatz PE. Atypical carcinoid tumors of the lung. *J Thorac Cardiovasc Surg.* 1972;64(3):413-21. PMID: 5054879.
- Rekhtman N. Neuroendocrine tumors of the lung: an update. *Arch Pathol Lab Med.* 2010 Nov;134(11):1628-38. doi: 10.5858/2009-0583-RAR.1.
- Caplin ME, Baudin E, Ferolla P, Filosso P, Garcia-Yuste M, Lim E, et al, ENETS consensus conference participants. Pulmonary neuroendocrine (carcinoid) tumors: European Neuroendocrine Tumor Society expert consensus and recommendations for best practice for typical and atypical pulmonary carcinoids. *Ann Oncol.* 2015 Aug;26(8):1604-20. doi:10.1093/annonc/mdv041.
- World Health Organization. Global Tuberculosis Report 2023 [Internet]. [Accessed: 7-Nov-2023]. Available from: [www.who.int/publications/news-room/fact-sheet/detail/tuberculosis](http://www.who.int/publications/news-room/fact-sheet/detail/tuberculosis).
- Nenekidis I, Stathopoulos GT, Anagnostakou V, Kokkori A, Dedeilias P, Kokotsakis J, et al. Atypical pulmonary carcinoid tumour in a 28-year-old nonsmoker with Prader–Willi syndrome. *Eur Respir J.* 2011;38(5):1230-3. doi:10.1183/09031936.00034711.
- Gosain R, Mukherjee S, Yendamuri SS, Iyer R. Management of typical and atypical pulmonary carcinoids based on different established guidelines. *Cancers.* 2018;10(12):510. doi:10.3390/cancers10120510.
- Rosado de Christenson ML, Abbott GF, Kirejczyk WM, Galvin JR, Travis WD. Thoracic carcinoids: radiologic-pathologic correlation. *Radiographics.* 1999 May-Jun;19(3):707-36. doi:10.1148/radiographics.19.3.g99ma11707.
- Turrin M, Pontoriero FM, Fiorentù G, Grisostomi G, Zampieri F, Savoia F, et al. Tracheal atypical solitary carcinoid in a so called "difficult asthma": a diagnostic challenge. *Monaldi Arch Chest Dis.* 2023 Aug 2. doi: 10.4081/monaldi.2023.2586.
- Rajendran V, Iqbal, Kumar V. Atypical bronchial carcinoid masquerading as bronchial asthma. *J Assoc Physicians India.* 2015 Nov;63(11):69-70. PMID: 29900716.
- Bambulović Petrović R, Stojanović M, Mavija Z, Tomanić M, Milekić J. [Comparison of characteristics of pulmonary tuberculosis in patients with and without diabetes]. *Biomed Istraž.* 2017;8(2):105-12. doi:10.7251/BII1702105B. Serbian.
- Dara M, Sotgiu G, Zaleskis R, Migliori GB. Untreatable tuberculosis: is surgery the answer? *Eur Respir J.* 2015;45:577-82. doi:10.1183/09031936.00229514.
- Harris HW. The evaluation and preparation for surgery of patients with pulmonary tuberculosis. *Am J Cardiol.* 1963 Sep;12:327-9. doi: 10.1016/0002-9149(63)90221-2.
- Juhn YJ. Risks for infection in patients with asthma (or other atopic conditions): is asthma more than a chronic airway disease? *J Allergy Clin Immunol.* 2014;134:247-57.e3. doi:10.1016/j.jaci.2014.04.024.
- Srećić M, Latinčić M, Lacković LN. [Association between tuberculosis and lung cancer – our results]. *Respiratio.* 2018;8(1-2):62-5. doi:10.26601/rsp.aprs.18.8. Serbian.
- Orakwe OI, Ukekwe FI, Okwulehie V, Iloanusi N, Aghaji M. Bronchial carcinoid tumors: A rare malignant tumor. *Niger J Clin Pract.* 2015 Sep-Oct;18(5):698-701. doi: 10.4103/1119-3077.158985.