



Radiological Changes in Leprosy Patients With Disabilities and Deformities of Hands and Feet

Sunakshi Sharma,¹ Vikas Malgotra,² Mashkoor Wani¹

Abstract

Background/Aim: Leprosy (Hansen's disease) affects the skin and nerves. Hands and feet are commonly involved in all types of leprosy often leading to deformities. This study explored radiological changes in leprosy patients with hand and foot disabilities/deformities.

Methods: Observational retrospective study was the chosen design. Study was conducted on 50 leprosy patients presenting at a tertiary care hospital with hand and foot disabilities during 2020-2022. Leprosy types were clinically diagnosed, confirmed by acid-fast bacilli staining. Bacteriological index (BI) and morphological index (MI) were calculated *via* Ridley's scale. Histopathological examination of the skin lesions was also conducted. Radiological exams, anteroposterior and lateral X-rays, identified specific/non-specific bone changes.

Results: Mean age was 38.8 years, bone changes identified at 40.3 years. Radiological changes were seen in 42.0 % patients (34 % patients had non-specific and 16 % had specific changes). These changes were seen more common and earlier in females as compared to males, the difference however was not significant ($p = 0.6$). Mean BI (2.8) and MI (32 %) of the patients with bone changes were slightly higher than those without bone changes but the differences were not statistically significant (2.2 and 27 %) ($p = 0.2$). Common specific changes were periostitis and subarticular erosion while osteopenia and phalangeal resorption were the most common non-specific changes.

Conclusion: Non-specific bone changes were more common than specific ones and in females as compared to males. Lepromatous leprosy (LL) was associated with maximum bone changes with varied involvement in other types of leprosy.

Key words: Leprosy bone changes X-ray; Bone changes in leprosy; Leprosy radiological changes; Leprosy specific and non-specific changes.

1. Department of Dermatology, Government Medical College, Jammu, India.
2. Department of Dermatology, Government Medical College, Udhampur, India.

Citation:

Sharma S, Malgotra V, Wani M. Radiological changes in leprosy patients with disabilities and deformities of hands and feet. Scr Med. 2024 May-Jun;55(3):385-90.

Corresponding author:

VIKAS MALGOTRA
E: drvikas2911@gmail.com

Received: 3 March 2024
Revision received: 21 May 2024
Accepted: 21 May 2024

Introduction

Leprosy, also known as Hansen's disease, is a chronic granulomatous infectious disease caused by *Mycobacterium leprae*. It primarily affects the skin and nerves, with nerve damage leading to sensory/motor impairments, deformities and

disabilities leading to substantial social and economic consequences.

Systemic manifestations of leprosy have been well-documented in the literature. In addition

to the skin and peripheral nerves, other tissues commonly affected by leprosy include bones, eyes, upper respiratory tract, kidneys, liver and testes. The occurrence of bone changes in leprosy has been reported to vary significantly in different studies. Hands and feet are commonly involved in all types of leprosy. According to a study on bone changes, approximately 25 % of untreated leprosy patients may develop deformities in their hands and feet, while about 80 % of joint lesions may involve metatarsophalangeal joints of the foot or the inter-phalangeal joints of the hands and feet.¹

The main focus of this study was to analyse the radiological changes observed in the hands and feet of leprosy patients with deformities.

Methods

Retrospective observational study was performed. Fifty leprosy patients with disabilities of hands and feet who attended the leprosy clinic were included in this observational retrospective study conducted at the Department of Dermatology at the Tertiary Care Hospital, Jammu, India, over 24 months (2020-2022). All the patients had grade I disability with 12 patients additionally having grade II disability (deformity) of hands and feet. Ethical clearance for the study protocol was obtained from the institutional ethical committee and informed consent was taken from all the patients.

The provisional diagnoses of the patients were classified into different types of leprosy based on the clinical examination: lepromatous (LL), borderline lepromatous (BL), borderline (BB), borderline tuberculoid (BT), tuberculoid (TT) and pure neuritic leprosy (PNL). To confirm the type of leprosy, acid-fast bacilli (AFB) were demonstrated through slit skin smears. The bacteriological index (BI) and morphological index (MI) were calculated according to Ridley's scale. Moreover, a histopathological examination of the skin lesions in cases of lepromatous, borderline and tuberculoid leprosy was conducted.

In addition to clinical and histopathological assessments, radiological examinations were performed on the selected patients. X-rays, including

antero-posterior (AP) and lateral of the patients' hands and feet, were thoroughly studied to identify any bone changes. These changes were further classified into specific and non-specific categories.

Statistical analysis was conducted on the collected data using appropriate methods. Descriptive data, including numbers and percentages, were analysed for all the categories examined in the study.

Results

Mean age of patients was 38.8 ± 11.6 years. Bone changes were seen at a mean age of 40.3 years. This study involved 35 males and 15 females with lepromatous leprosy (LL) accounting for the maximum number of patients (20) followed by BL (12), BT (11), BB (3) and PNL (4) (Figure 1). However, bone changes were seen in 53 % females and 37 % males. Bone changes were seen in females at a mean age of 38.6 ± 16.1 years and in males at 41.4 ± 8.9 years ($p = 0.6$). Mean BI (2.8) and MI (32 %) of the patients with bone changes were slightly higher than those without bone changes but the differences were not statistically significant (2.2 and 27 %) ($p = 0.2$).

Radiological changes were seen in 21 patients (42 %). Specific radiological changes were present in 8 patients (16 %) and non-specific changes were seen in 17 patients (34 %). Primary periostitis and subarticular erosion were the most common specific radiological finding present in 4 (8 %) and 3 (6 %) patients respectively (Table 1). Osteopenia and resorption of terminal phalanges were the most common non-specific findings in study seen in 5 (10 %) and 4 (8 %) patients, respectively.

The maximum number of patients with bone changes had LL (13 patients or 26 %). Other types of leprosy in patients having bone changes with different frequency were: BL - 5 (10 %), PNL - 2 (4 %), BB - 1 (2 %). Specific bony changes were seen in multibacillary patients, while the non-specific changes were seen in paucibacillary and multibacillary patients (Figure 2). Some examples of bone changes are shown in Figure 3 and Figure 4.

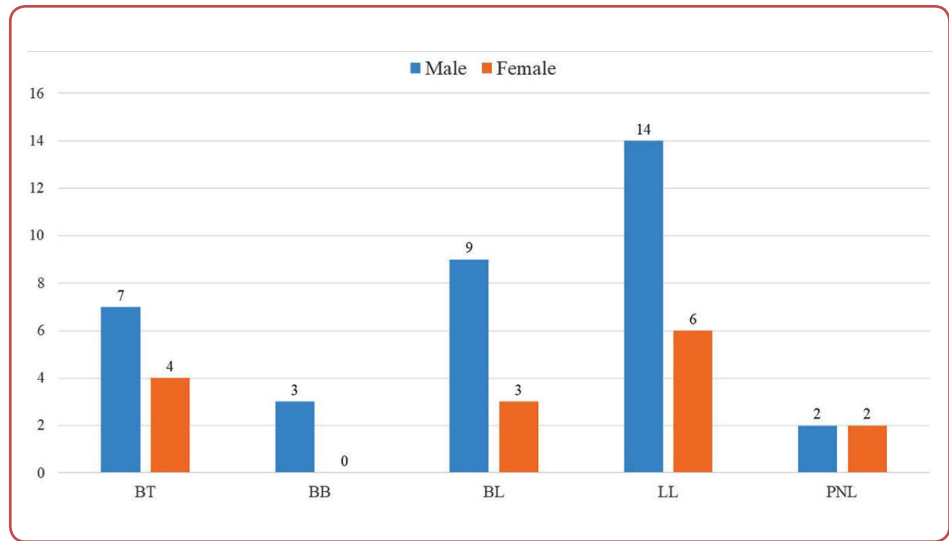


Figure 1: Gender distribution of different types of leprosy seen in the patients.

LL: lepromatous; BL: borderline lepromatous; BB: borderline; BT: borderline tuberculoid; TT: tuberculoid; PNL: pure neuritic leprosy;

Table 1: Presented bone deformities in patients with leprosy

Type	Deformity	Total	Hands	Feet	Hands and feet
Specific	Primary periostitis	4	2	1	1
	Subarticular erosion	3	3	-	-
	Honeycombing	2	-	-	2
	Sclerosis	2	-	2	-
	Areas of bone destruction	1	-	1	-
Non-specific	Osteopenia (periarticular/diffuse)	5	5	-	-
	Resorption of terminal phalanges	4	2	1	1
	Bone erosions	3	2	1	-
	Joint subluxation/ dislocation	3	3	-	-
	Joint contractures	3	-	3	-
	Soft tissue thickening	2	2	-	-
	Secondary periostitis	2	1	-	1
	Hitchhiker's deformity	1	1	-	-
	Joint destruction	1	1	-	-

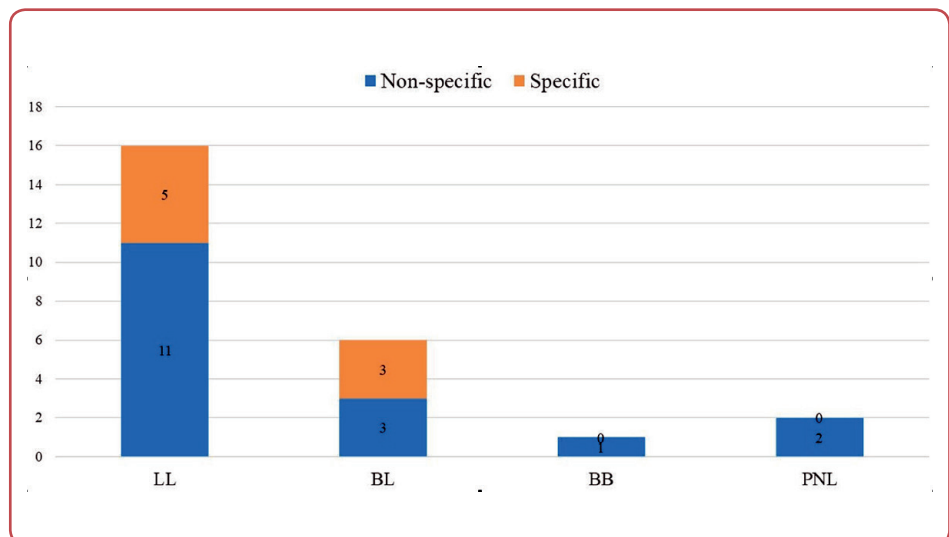


Figure 2: Types of bone changes seen in the studied patients

LL: lepromatous; BL: borderline lepromatous; BB: borderline; BT: borderline tuberculoid; TT: tuberculoid; PNL: pure neuritic leprosy;

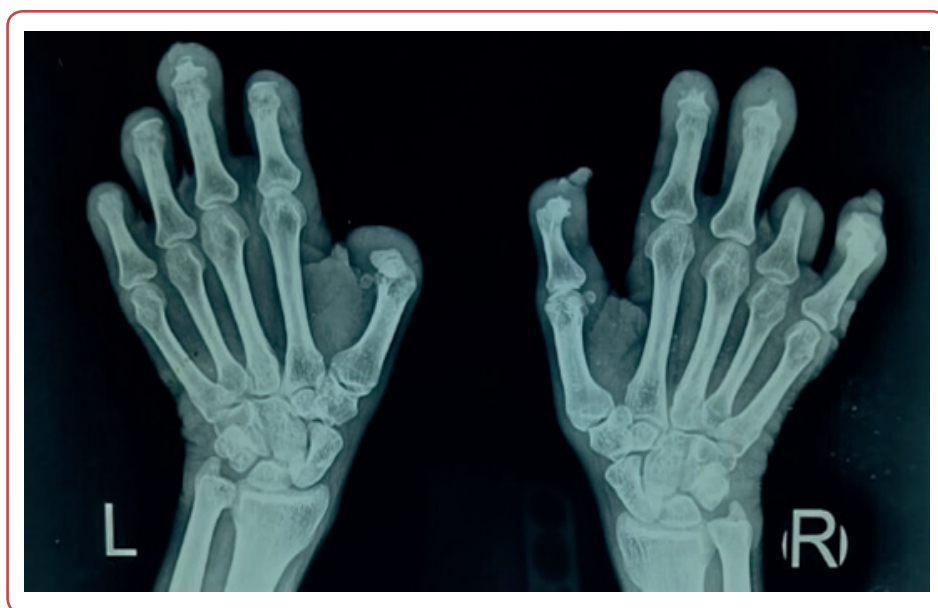

Figure 3: X-ray of hands and wrist joint (AP) of a patient with lepromatous leprosy (LL) showing: complete resorption of all terminal phalanges of both hands, partial resorption of all middle phalanges of both hands except the 4th digit of the right hand which shows complete resorption along with partial resorption of proximal phalanx. Soft tissue thickening also seen in digits of both hands with periarticular osteopenia.

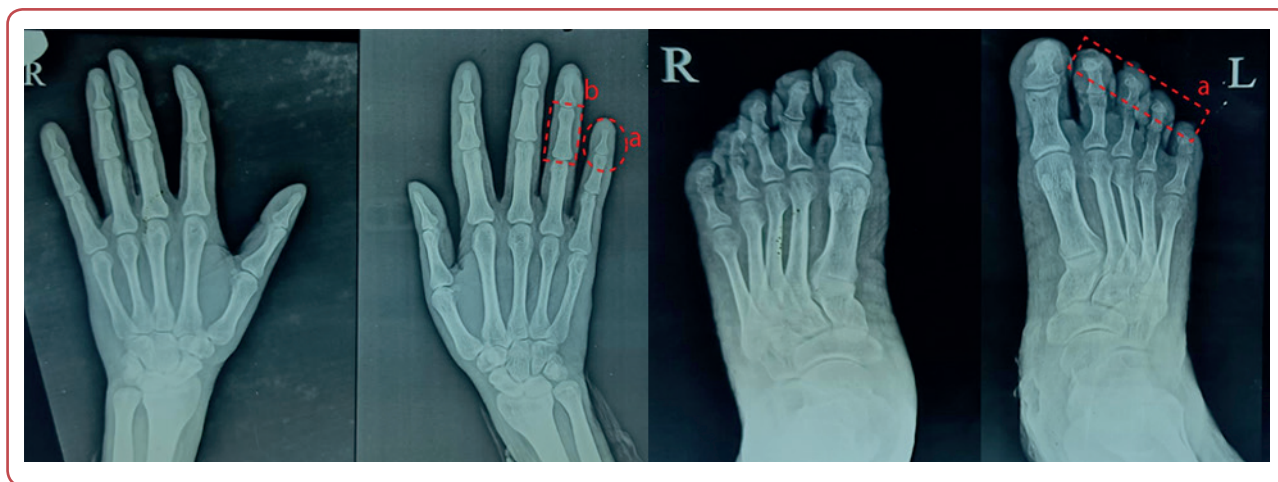

Figure 4: X-ray of the hands and feet (AP) showing: a) resorption of terminal phalanx of 5th digit with subarticular erosion of middle phalanx of left hand, resorption of most of the terminal phalanges of both feet; b) periarticular osteopenia seen in multiple interphalangeal joints of both feet; c) osteoporotic changes associated with cortical thinning seen in middle phalanges of 2nd, 3rd, 4th and 5th digits and metacarpals of left hand.

Discussion

This study aimed to analyse the radiological changes observed in the hands and feet of leprosy patients with deformities. The mean BI and MI of patients with bone changes were slightly higher than those without bone changes but the differences were not statistically significant. This suggests that the presence of bone changes

were not strongly associated with bacterial or morphological indices. In addition, bone changes were seen more commonly and at an earlier mean age (38.6 years) in females as compared to males (41.4 years), the difference however was not significant.

Bone changes in leprosy may be specific- when they occur due to direct invasion by *Mycobacterium leprae* or non-specific when they occur indirectly due to sensory impairments, repeated trauma, trophic changes and restricted movements of muscles. Radiological changes were detected in 21 out of the 50 patients, resulting in an overall incidence of bone changes at 42.0 %, which was lower than reported in studies conducted by Choudhuri et al (87.3 %) and Thappa et al (82.9 %).^{2, 3} The most common specific radiological finding was primary periostitis and subarticular erosion, whereas osteopenia (subperiosteal or diffuse) and resorption of terminal phalanges were the most common non-specific changes observed in presented study. Specific bony changes were seen in multibacillary patients, while the non-specific changes were seen in paucibacillary and multibacillary patients.

Specific bone changes in leprosy have been noted to be rare with an estimated prevalence of 3 % to 5 % among hospitalised patients.⁴ However, an increased incidence of specific changes was noted (16 %) perhaps because this study was conducted on patients having disabilities/deformities. In addition, non-specific radiological changes were two times more common (34 %) than specific changes (16 %), the results being consistent with previously conducted studies.^{2, 5, 6} Regarding the distribution of radiological changes across different types of leprosy, this study revealed interesting patterns. Lepromatous leprosy (LL) was associated with the highest number of patients (13 patients or 26 %) exhibiting radiological alterations. This aligns with previous studies that have consistently shown a higher prevalence of bone involvement and deformities in lepromatous leprosy.⁷ Among the other types of leprosy, 3 patients (6 %) with borderline lepromatous (BL) leprosy exhibited specific changes, while 3 patients (6 %) displayed non-specific changes. There was no patient with a diagnosis of TT in presented study. In addition, patients with BT leprosy did not have any bone involvement. Moreover, LL and BL accounted for the highest percentage of patients (32 %) with bone changes. These findings are in agreement with the fact that bone involvement in paucibacillary leprosy (PB) is relatively uncommon and indicate the importance of considering leprosy type when evaluating bone pathology.

The observed mean age of patients in presented

study was 38.8 ± 11.6 years and bone changes were seen at a mean age of 40.3 years. While age has been identified as a contributing factor to the development of deformities in leprosy patients, study did not specifically explore age-related differences in radiological changes. Further investigations with larger sample sizes and age-stratified analyses would provide more comprehensive insights into the relationship between age and radiological changes in leprosy patients.

Conclusion

This study revealed that while specific radiological changes were relatively rare, they occurred with a notable incidence in patients with disabilities/deformities, particularly in those with multibacillary forms of leprosy. Non-specific changes, on the other hand, were more prevalent and occurred in both paucibacillary and multibacillary patients, underlining the broader impact of the disease beyond the direct effects of the *Mycobacterium leprae* infection. It highlights slight differences in gender with a higher incidence noted in female patients, although this difference was not statistically significant. In conclusion, this study contributes to the understanding of the radiological manifestations of leprosy in affected patients and underscores the importance of comprehensive diagnostic evaluations in the management of this debilitating disease.

Ethics

The study was approved by the Institutional Review Board at GMC Jammu (decision No IEC/GMC/2020/247, dated 20 October 2020). Written informed consent was obtained before the study. The procedures adhered to the ethical guidelines of the Declaration of Helsinki.

Acknowledgement

None.

Conflicts of interest

The authors declare that there is no conflict of interest.

Funding

This research received no specific grant from any funding agency in the public, commercial, or not-for-profit sectors.

Data access

The data that support the findings of this study are available from the corresponding author upon reasonable individual request.

Author ORCID numbers

Sunakshi Sharma (SM):
0000-0002-5387-3249
Vikas Malgotra (VM):
0000-0002-1839-2589
Mashkooor Wani (MW):
0009-0008-5091-8537

Author contributions

Conceptualisation: SM, MW
Methodology: SM, MW
Software: SM, VM
Validation: VM
Formal analysis: SM, VM
Investigation: SM, VM, MW
Resources: SM, VM
Data curation: SM, MW
Writing - original draft: SM, VM
Writing - review and editing: SM, VM, MW
Visualisation: SM, VM, MW
Supervision: SM, MW
Project administration: SM, VM

References

1. Ankad Balachandra S, Hombal A, Sudhakar R, Naidu Varna M. Radiological changes in the hands and feet of leprosy. *J Clin Diagnostic Res.* 2011;5(4):703-7.
2. Choudhuri H, Thappa DM, Kumar RH, Elangovan S. Bone changes in leprosy patients with disabilities/deformities (a clinico-radiological correlation). *Indian J Lepr.* 1999 Apr-Jun;71(2):203-15. PMID: 10506954.
3. Thappa DM, Sharma VK, Kaur S, Suri S. Radiological changes in hands and feet in disabled leprosy patients: a clinico-radiological correlation. *Indian J Lepr.* 1992 Jan-Mar;64(1):58-66. PMID: 1533411.
4. Moonot P, Ashwood N, Lockwood D. Orthopaedic complications of leprosy. *J Bone Joint Surg Br.* 2005;87-B(10):1328-32. doi:10.1302/0301-620X.87B10.16596.
5. Paterson DE, Rad M. Bone changes in leprosy, their incidence, progress, prevention and arrest. *Int J Lepr.* 1961 Oct-Dec;29:393-422. PMID: 14484319.
6. Mohammad W, Malhotra SK, Garg PK. Clinico-radiological correlation of bone changes in leprosy patients presenting with disabilities/deformities. *Indian J Lepr.* 2016 Apr;88(2):83-95. PMID: 29757540.
7. Reddy KB, Sreedevi L, Suryanarayana S. Study of radiological changes of bones in leprosy patients. *Ann Int Med Den Res.* 2017; 4:5-8. doi: 10.21276/aim-dr.2018.4.1.dt2.