



ORIGINAL ARTICLE

doi:10.18575/msrs.sm.e.16.02
UDC: 616.348-006.6
COBISS.RS-ID: 5701400

Complications of Loop Ileostomy upon the Creation of Low Colorectal Anastomosis

**Jugoslav Đeri,¹
Milan Simatovic,¹
Velimir Škrbić,¹
Slaviša Mihajlović²**

¹ University Clinical Center of the Republic of Srpska, Clinic of General and Abdominal Surgery of General and Abdominal Surgery
² Health Institute, Drvar

ABSTRACT

Introduction. The protective ileostomy is a procedure that is now increasingly used after the creation of low colorectal anastomosis, and after resection of rectal cancer. The protective ileostomy is a procedure that, to a lesser extent, affects the prevention of anastomotic colorectal dehiscence, but it has a much greater significance in reducing the severity of complications occurring after colorectal anastomosis dehiscence. However, the creation itself, as well as the closure of loop ileostomy are accompanied with certain complications.

Aim of the study. The aim of this study was to determine the frequency and severity of complications of ileostomy and justification for its creation, within the test sample of 42 patients.

Patients and Methods. The study was designed as a retrospective-prospective study. 42 patients, with created protective ileostomy that occurred after low colorectal anastomosis, were included in the study. The average age was 64.38 years with a standard deviation of 9.63 years. The youngest patient was 36 years old and the oldest patient was 77 years old. The representation of patients by gender was 29 (69%) male patients and 13 (31%) female patients. During the study, functions and complications associated with the created loop ileostomy, as well as the need for surgical treatment and the period until the sinking of ileostomy were monitored in patients.

Results. Out of the total number of observed patient complications of ileostomy occurred in 8 of them (19%), and in 34 (81%) patients there were no complications. Out of the total number of complications, only in cases of 2 (4.8%) patients, there was the need for surgical treatment. In 1(2.4%) patient, ileostomy remained permanently.

Conclusion. This study showed that the loop ileostomy after the creation of low colorectal anastomosis is accompanied with fewer complications. The resulting complications are successfully disposed by conservative treatment, and only rarely require surgical re-intervention.

Keyword: loop ileostomy, rectal cancer, complications of loop ileostomy

Contact address:

Jugoslav Đeri
Department of General and Abdominal Surgery
University Clinical Center Banja Luka
Dvanaest beba
78000 Banja Luka, RS
Bosnia and Hercegovina
E-mail: djeri@blic.net
Tel(mob) : +38765601777

(Scr Med 2016:47:11-15)

Submitted: November, 27th 2015
Accepted: December, 30th 2015

Introduction

The first application of ileostomy dates back to the nineteenth century, and over time the technique of its creation and application of ileostomy has changed and improved.¹

Today, there are numerous indications for the creation of bipolar ileostomy but lately it has been increasingly used routinely in order to protect the low colorectal anastomosis and coloana.² The optimal location for creation of ileostomy must be determined for each patient individually, but generally there is a typical place located at the junction of the first and second third of the line connecting the umbilicus with spine iliac bone.³ The creation of loop ileostomy causes many physical and psychological problems for patients, so that the mere occurrence of complications can additionally worsen the patient's life and significantly impair its quality. The occurrence of complications increases costs of treatment and causes slower recovery of patients' daily life activities.⁴ Complications of protective ileostomy occur mostly as a result of errors in surgical technique, and to a lesser extent due to progression of the underlying disease, and other technical factors. Complications can be early and late. Early complications are bleeding, retraction of the stoma, which occurs in 15% of cases, necrosis, and parastomal abscesses and phlegmon.⁵ Late complications, such as prolapsed stoma, stoma stenosis and parastomal hernias with ileostomy, are relatively rare and occur in 3% cases.⁶ Today, there are opposing views on the role of loop ileostomy to protect low colorectal anastomosis-the occurrence of dehiscence to a reduction in death in patients who have already suffered dehiscence.⁷ Complications of ileostomy may occur in over 25% of patients.⁸ In order to obtain good results in the treatment of complications, each patient requires an individual treatment, special care, persistence and team work between doctors and nurses.⁸

Aim of the study

The aim of the study was to determine the function of protecting ileostomy, the occurrence of complications of ileostomy within the observed study and from the first postoperative day until its closure. Furthermore, the aim of the study was to determine the need for surgical treatment of complications and to determine the justification for creating a loop ileostomy.

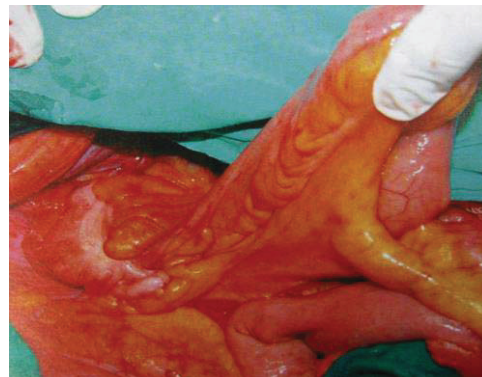
Patients and Methods

The study was designed as a retrospective-prospective study. 42 patients with low colorectal anastomosis after which the creation of protective ileostomy occurred were included in the study. All patients were similar in age and sex. Data for the study such as gender, age, operating results, and complications were used from the

medical records, operational protocols and clinical examination of the patients treated at the Clinic of General and Abdominal Surgery of the Clinical Center in Banja Luka. Surgical technique of patients included the usage of low rectal resection technique with sharp excision by thermocauter and Ligasure, under direct visual control outside the visceral fascia that covered the rectum and mesorectum. Resection of the lower mesenteric vessels was conducted in high ligation. At the same time, an adequate hemostasis was performed with the usage of ligatures and slow-resorption suture material and Ligasure.

Total mesorectal excision was performed in patients with rectal tumors at the distance of 10 cm from the ano acute line. In most cases, the resection was performed with linear TA stapler. In a small number of patients, resection of the rectum was performed with a stapler for low anterior resection (contour). The anastomosis was created using the mechanical circular stapling devices (staplers). All patients who were likely to create loop ileostomy were informed about that additional procedure prior to the operation, and they had to sign the consent form. The final decision on the need to create a protective ileostomy was made during the operation. The decision depended on the existence of factors that may have threatened the anastomosis as well as the experience of the surgical team. For most of the coloanal anastomosis, anastomosis protection with the creation of protective ileostomy was performed. Standard surgical techniques were applied in the creation of loop ileostomy. In the lower right quadrant of the abdomen, on the line that connected the front upper belly button and pelvic bulge protective ileostomy was created. 5 cm long ileum winds was performed through an opening at about 15cm of Bauhin's valve. (Picture 1.) Then the rear edges of the vagina rectus and peritoneum were fixated to serosa cancer with 4 3-0 stitches of slow resorptive material.

Picture 1. Preparation of the intestine to create a loop ileostomy



Then the everted intestine was fixated to the surface of the skin with individual stitches 3-0. In this way, the creation of adhesion was minimal and it allowed easier

closure of ileostomy subsequently. The functioning of the stoma, the occurrence of complications and determining the severity of complications was monitored through regular patients' follow-ups. Averagely, the closure of ileostomy was individually conducted 200 days after its creation with prior verification anastomosis.

Results

The protective ileostomy was created in 42 patients. The average age was 64.38 years with a standard deviation of 9.63 years. The youngest patient was 36 years old and the oldest patient was 77 years old.

Out of 42 patients, 8 patients (19%) had complications of ileostomy and 34 patients were without complications (Graph 1.). Patients who had complications of ileostomy with or without the operation were classified in the group of patients who had complications of ileostomy.

Graph. 1. Distribution of patients in those who had or did not have complications of ileostomy

| Complications of ileostomy | N | % |
|----------------------------|----|-------|
| Yes | 8 | 19.0 |
| No | 34 | 81.0 |
| Total | 42 | 100.0 |

Based on the results of χ^2 test ($\chi^2 = 16,095$; $p = 0.000$), the conclusion was that there was a statistically significant difference ($p < 0.05$) in the number of patients who had complications of ileostomy and the ones who did not. The number of patients who did not have complications of ileostomy was significantly higher than that of patients who had them. Number of patients who underwent the repeated operation due to the complications of ileostomy was 2 (4.8%) (Graph 2).

Graph 2. Patients who underwent the repeated surgical treatment

| | Broj pacijenata | |
|-------|-----------------|-------|
| | N | % |
| Yes | 2 | 4.8 |
| No | 40 | 95.2 |
| Total | 42 | 100.0 |

Based on the results of χ^2 test ($\chi^2 = 34,381$; $p = 0.000$), the conclusion was that there was a statistically significant difference ($p < 0.05$) in the number of patients who underwent the repeated surgical treatment due to

complications of ileostomy and those who did not undergo the repeated surgical treatment. Furthermore, it can be concluded that the risk of surgery, which occurred due to complications ileostomy, was very low. The number of patients with permanent ileostomy was 1 (2.38%) (Graph. 3.). Based on the results of χ^2 test ($\chi^2 = 27,524$; $p = 0.000$), the conclusion was that there was a statistically significant difference ($p < 0.05$) in the number of patients with closed protective ileostomy and patients with permanent ileostomy. Number of patients with closed loop ileostomy was substantially greater.

Graph. 3. Distribution of patients in the group with permanent ileostomy and the group with the closed stoma.

| Permanent ileostomy | Broj pacijenata | |
|---------------------|-----------------|-------|
| | N | % |
| Yes | 1 | 2.38 |
| No | 41 | 97.62 |
| Total | 42 | 100.0 |

Minimal elapsed time until the closure of loop ileostomy was 40 days, while maximum was 445 days. The average elapsed time until the closure of loop ileostomy was 219.03 days with a standard deviation of 111.342 days. Protective ileostomy was never closed in 1 patient as it was the case of permanent ileostomy.

Discussion

Most often, subocclusive problems occur as a result of postoperative adhesions and stenosis due to retraction of the stoma or peristoma infections. Irritation and mild skin necrosis was present in 2 patients. Stoma necrosis can occur in almost 17% of patients with stoma. Most often necrosis occurs as a result of excessive devascularisation and negligent compression and stretching of the mesentery bowel. It manifests itself by changing the color of the stoma from livid to black. In 2 patients, complications occurred in more severe form. In 1 patient, it was the case of ileostomy prolapse, and in another case it was a subocclusive problem with radiological picture of ileus. Both cases required the surgical treatment of complications. Prolapse can be milder or to a greater extent when it causes the stoma defunctioning. Prolapsed stoma can be reponed, but the operation is a definite treatment. In their study, Ramli and associates have also found that the stoma prolapse and stoma herniation is one of the most frequent complications that occur after the creation of loop ileostomy. They allege that these complications are often associated with aging of patients, diet and other comorbidities.

In his study, Salvadalena pointed to irritation and necrosis of parastomal skin as frequent complications that occur after the created loop ileostomy. He monitored 43 patients over a period of 3 months after the surgery. Patients were monitored for 7 days after the creation of stoma, and after 2, 6 and 12 weeks. The study found that the complication most often occurred between 21st and 40th postoperative day. All patients were treated by highly experienced and trained nurses in the centers for the stoma in the United States. This study showed improved results of conservative treatment thanks to the constant and professional monitoring.¹⁰

In our study, 1 patient experienced complications after the closure of ileostomy. In his case, he required a new surgical intervention with resection of the small intestine and creation of new anastomosis. Permanent ileostomy remained in 1 patient. In patients with permanent ileostomy, it was the case of relapse and progression of the underlying disease, and the closure of the previously created loop ileostomy was excluded. From 2001 to 2012, Perez Domingos and associates conducted the study which included 96 patients with a created loop ileostomy after low anterior resection and conducted TME. The study followed morbidity and mortality after the creation of ileostomy. The study stated that the complications after the sinking of ileostomy were up to 24%. The study included patients in whom the closure of ileostomy did not occur, that is, patients with permanent ileostomy. Closing of the stoma was averagely performed 152 days after its creation. Permanent stoma remained in 5 patients. Closure period was longer in patients who had undergone chemotherapy. The study showed that the protective ileostomy was associated with low mortality and slightly higher morbidity.¹¹ Significant differences in the percentage of complications after closure of ileostomy, when compared to our study, can be explained by the fact that our study only monitored complications in patients who required surgical treatment in the management, not all complications associated with sinking of ileostomy. In the period from 2003 to 2010, Dinnewitzer and associates conducted the study on 125 patients with a loop ileostomy after low colorectal anastomosis. Its goal was to determine how many patients would, in 5-year period, eventually have the permanent stoma. The main reasons for the temporary stoma to become permanent were in the majority of anastomotic dehiscence and in almost 60% of patients. To a lesser extent, in 27% of cases the reason was resistant fecal incontinence, while in 13% the reason was local recurrences. The total number of patients with the permanent stoma was 6.¹² The average elapsed period until the closure of ileostomy in our study was 219 days, which was more than the normal average. Similar results were obtained in the study

conducted by Phatak and associates, where the average period until the closure of ileostomy was about 7 months.¹³ Postoperative treatment of patients with chemotherapy and radiotherapy are the most common reasons for the delays in the closure of the protective ileostomy.¹¹ Complications that occur as a result of created ileostomy are generally of milder degree and in most cases can be resolved conservatively.

Conclusion

This study has showed that the complications associated with the created loop ileostomy are mostly mild and successfully disposed with conservative treatment. Furthermore, the study has shown that there is full justification for the creation of ileostomy after low colorectal anastomosis. In patients who were treated with postoperative chemoradiotherapy, the time period until the closure of ileostomy was significantly extended.

References

1. Franks K colectomy or resection of the large intestine for malignant disease. *Trans Med Chir* 1889; 72: 211-232. <http://dx.doi.org/10.1177/095952878907200113> PMID:20896745 PMCID:PMC2121537
2. Williams NS, Nasmyth DG, Jones D, Smith AH. De-functioning stomas: a prospective controlled trail comparing illeostomy loop with loop transverse colostomy. *Br J Surg* 1986; 73 (7): 566-570. <http://dx.doi.org/10.1002/bjs.1800730717> PMID:3524742
3. Hulten L, Kock NG Ileostomy and reconstructive surgery of the gastrointestinal tract. Butterworths, 1985 111-134.
4. Michael RB, Keighley, Norman S, Williams, Surgery of the anus, rectum and colon. WB Saunders, 1993: 139-239
5. Zoran Gerzić B. et al. Complications in digestive surgery. *Zavod za udzbenike I nastavna sredstva Beograd* 2000: 555-561
6. Leong APK, London-Schimmer EE, Phillips RKS, Life table analysis of stomal complications following an ileostomy. *Br J Surg* 1994; 81: 722-729. <http://dx.doi.org/10.1002/bjs.1800810536>
7. Pollard CW, Nivatvongs S, Rojanasakul A, Ilstrup DM. Carcinoma of the rectum. Profiles of intraoperative and early postoperative complications, *Dis Colon Rectum* 1994; 37: 866-74. <http://dx.doi.org/10.1007/BF02052590> PMID:8076485
8. M Barber, enterostomy complications and their treatment; Institute of oncology, Sremska Kamenica, 1995
9. Ramly EP, Crosslin T, Orkin B, D Popowich Strangulated ileostomy evisceration following lateralizing mesh repair of parastomal hernia. *Hernia*. 2014 May 29th.

- <http://dx.doi.org/10.1007/s10029-014-1259-z>
PMid:24777430
10. Salvadalena GD. The incidence of stoma and peristomal complications during the first 3 months after ostomy creation. *J Wound Ostomy Continence Nurs.* 2013 Jul-Aug; 40 (4): 400-6.
<http://dx.doi.org/10.1097/WON.0b013e318295a12b>
PMid:23820472
 11. Pérez Domínguez L, García Martínez MT, Cáceres Alvarado N, Toscano Novella A Higuero Grosso AP, Casal Núñez. Morbidity and mortality of temporary diverting ileostomies in rectal cancer surgery. *Cir Esp.* 2014 June 23rd. PMid: 24969349
 12. A Dinnewitzer, Jäger T, Nawara C, S Buchner, Wolfgang H, Öfner D. Cumulative incidence of permanent stoma after sphincter preserving low anterior resection of mid and low rectal cancer. *Dis Colon Rectum.* 2013 Oct; 56 (10): 1134-42.
<http://dx.doi.org/10.1097/DCR.0b013e31829ef472>
PMid:24022530
 13. Phatak UR, As LS, You YN, Rodriguez-Bigas MA, Skibber JM, Feig BW, Nguyen S, Cantor SB, Chang GJ. Impact of ileostomy-related complications on the multidisciplinary treatment of rectal cancer. *Ann Surg Oncol.* 2014 Feb; 21 (2): 507-12.
<http://dx.doi.org/10.1245/s10434-013-3287-9>
PMid:24085329 PMCID:PMC4026258

Komplikacije protektivne ileostome nakon kreiranih niskih kolorektalnih anastomoza

SAŽETAK

Uvod. Protektivna ileostoma je procedura koja se danas sve više koristi nakon kreiranja niske kolorektalne anastomoze, a poslije resekcije karcinoma rektuma. Protektivna ileostoma je procedura koja u manjoj mjeri utiče na sprečavanje dehiscencije kolorektalnih anastomoza, ali ona ima i mnogo veći značaj u smanjenju težine komplikacija koje nastaju nakon dehiscencije kolorektalne anastomoze. Međutim, samo kreiranje, kao i zatvaranje protektivne ileostome praćeni su određenim komplikacijama.

Cilj rada. Cilj ove studije bio je da se unutar ispitivanog uzorka od 42 pacijenta utvrdi učestalost i težina komplikacija ileostome te opravdanost njenog kreiranja.

Ispitanici i metode. Istraživanje je koncipirano kao studija retrospektivno-prospektivnog karaktera. U istraživanje je bilo uključeno 42 pacijenta kod kojih je nakon niske kolorektalne anastomoze kreirana protektivna ileostoma. Prosječna starost pacijenata bila je 64,38 godina sa standardnom devijacijom od 9,63 godine. Najmlađi pacijent imao je 36 godina, a najstariji pacijent 77 godina. Zastupljenost pacijenata po polu bila je 29 (69%) pacijenata muškog pola i 13 (31%) pacijenata ženskog pola. Tokom studije, kod pacijenata je praćena funkcija kreirane ileostome te komplikacije povezane sa kreiranom protektivnom ileostomom, a zatim i potreba za hiruškim tretmanom kao i period do potapanja ileostome.

Rezultati. Od ukupnog broja posmatranih pacijenta, kod njih 8 (19 %) javile su se komplikacije ileostome, a kod 34(81%) pacijenata nije bilo komplikacija. Od ukupnog broja nastalih komplikacija, samo je u slučaju 2(4,8%) pacijenta bilo potrebe za ponavljanjem hiruškog tretmana. Kod 1(2,4%) pacijenta ileostoma je ostala trajno.

Zaključak. Ova studija je pokazala da su protektivne ileostome nakon kreiranih niskih kolorektalnih anastomoza praćene manjim brojem komplikacija. Nastale komplikacije se uspješno zbrinjavaju konzervativnim tretmanom, a samo rijetko zahtijevaju ponavljanje hiruške intervencije

Ključne riječi: Protektivna ileostoma, karcinom rektuma , komplikacije protektivne ileostome.