



ORIGINAL ARTICLE

doi:10.18575/msrs.sm.e.16.01
UDK: 616.348-006-089
COBISS.RS-ID:5697304

Surgical Treatment of Colorectal Cancer Metastases

ABSTRACT

Introduction. Colorectal metastatic liver tumors are the most common secondary liver tumors. During life, the liver metastases will develop either as synchronous or metachronous carcinomas in half of the total number of patients. At the time of the diagnosis, in approximately 25% of patients with colorectal cancer diagnosis, the presence of secondary deposits in the liver was observed, and additional 25% of patients were to develop metastases within five years.

Aim of the study. The objective was to demonstrate that anatomic resections of the liver present the method of choice in surgical treatment of colorectal liver metastases, when compared to metastasectomy.

Patients and methods. The study included 70 patients, divided into two groups. Among the patients from the first group, metastasectomy, which consisted of the removal of metastases and the surrounding liver parenchyma no more than 1cm with the usage of Kelly-clysis technique or Ligasure device, was performed. In patients from the second group, anatomic resection of the liver was performed upon which metastases were removed and the associated anatomical segment or section, that is, half of the liver depending on the number and localization of metastases.

Results. The average overall survival values for the first group was 36 months with a standard deviation of 4.8 months. The average overall survival in patients from the second group was 36 months with a standard deviation of 2.6 months. The average value of disease-free survival in the first group was 18 months with a standard deviation of 2.22 months. In the second group, the average disease-free survival was 22 months with a standard deviation of 0.74 months.

Conclusion. Overall survival in both types of operation was identical, and the average overall survival was 36 months. Disease-free interval in the anatomical resection was 22 months, while it was 18 months in metastasectomy. From all the above mentioned, it can be concluded that surgery is a fundamental and irreplaceable method in the treatment of liver metastases of colorectal cancer.

Key words: liver, metastasis, metastasectomy, anatomical resection

Velimir Škrbić,¹
Milan Simatović,¹
Jugoslav Đeri,¹
Goran Janjić,¹
Slaviša Mihajlović²

¹ University Clinical Center of the Republic of Srpska, Banja Luka
² Health Institute, Drvar

Contact address:

Škrbić Velimir
St. Bulevar Desanke Maksimović 16
78000 Banja Luka
Republic of Srpska
Bosnia and Herzegovina
Mo/ ++387 65 747 815
Email: velimirskrbico1@gmail.com

(Scr Med 2016:47:7-10)

Submitted: November 11th, 2015
Accepted: December 12th, 2015

Introduction

Colorectal cancer is the most common gastrointestinal malignant tumor that is also the most common liver tumor metastases.¹ At the time of the diagnosis, in approximately 25% of patients with colorectal cancer diagnosis, the presence of secondary deposits in the liver was observed, and additional 25% of patients were to develop metastases within five years.² The first liver resection for colorectal liver metastases was performed by Catell in 1940. With the improvement of surgical techniques, introduction of new cytostatics and reduction of the resection margin to less than 1 cm, the application of interventional radiology, portal venous embolization, allowed the transfer of patients from the group with unresectable tumors to group with resectable ones. The aim of treatment is surgical removal of all metastatic tumors in the liver, because the experience indicates to the five-year survival of 25-60% of the operated patients.² 70% of conservatively treated patients with metastases do not survive a year.³ Metastasectomies present the group of nonanatomic resection surgeries where the intersection of the hepatic parenchyma within 0.5-1 cm of the metastases is performed with the usage of Kelly-crysis or Ligasure technique. Anatomical liver resections are based on the principles of segmental and sector anatomy of the liver. The extent of anatomical surgery includes segmentectomies, bisegmentectomies, sectionectomies and hemihepatectomies.

Aim of the study

To establish whether anatomic resection of the liver is the method of choice in surgical treatment of colorectal liver metastases, when compared to metastasectomy, as well as to monitor the distance in disease-free time and overall survival.

Patients and methods

The research had the character of a retrospective-prospective study. The survey was conducted in the University Clinical Center of Banja Luka. The study covered the period from January 2007 to January 2014. The study was conducted on 70 patients, divided into two groups (group A and B). Criteria for inclusion in the study were respondents who were technically able to be taken care of by surgical method of metastasectomies and by method of anatomical resections. Metastatic disease was localized only in the liver.

The first group of respondents N = 35 (group A) underwent surgical metastasectomies of the tumor and the second group N = 35 (group B) underwent anatomical resection of the tumor.

In the group A patients, metastasectomy, which was consisted of removing metastases and surrounding liver parenchyma no more than 1cm with the usage of Keli-crysis

technique or Ligasure device, was performed. In group B patients, anatomic resection of the liver was performed upon which metastases were removed and the associated anatomical segment or section, that is, half of the liver depending on the number and localization of metastases.

The following surgical approaches were used: medial, J incision and Makuch laparotomy. After the opening, we accessed to the mobilization of the liver, followed by intraoperative ultrasonography (IOUSA), which provided the detection of the precise tumor position.

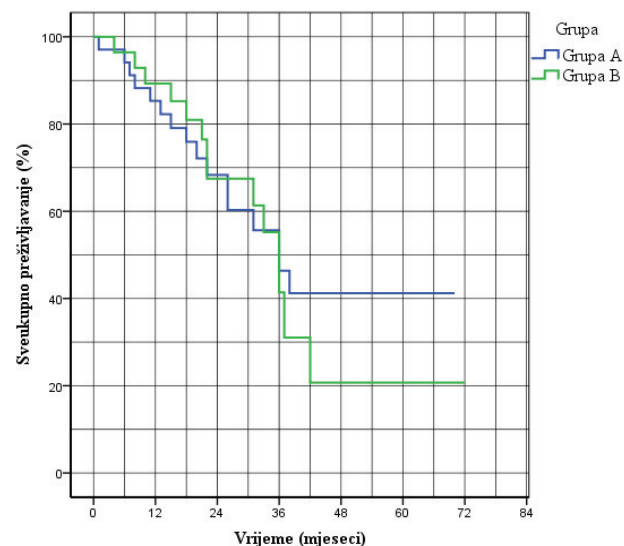
Liver resection was performed at reduced central venous pressure CVP (0-5 cm H2O), with the patient in Trendelenburg position. Parenchyma transection began with diathermy tag of resection line, while the section of parenchyma was performed by Ligasure or Kelly-crysis technique. Bilio-vascular structures were taken care of with clips and vascular sutures.

Results

The outcomes of the examined sample of overall survival based on Kaplan-Meier curves for patients from the group A who underwent metastasectomies, the median overall survival was 36 months with a standard deviation of 4.8 months and a one-year, two-year and three-year survival was 85.3%, 68.3% and 50%. (Chart 1.)

The average overall survival in group B patients, who underwent the anatomical surgery, was 36 months with a standard deviation of 2.6 months and a one-, two- and three-year survival was 89.3%, 67.5% and 50%.

Chart 1. Medial overall survival



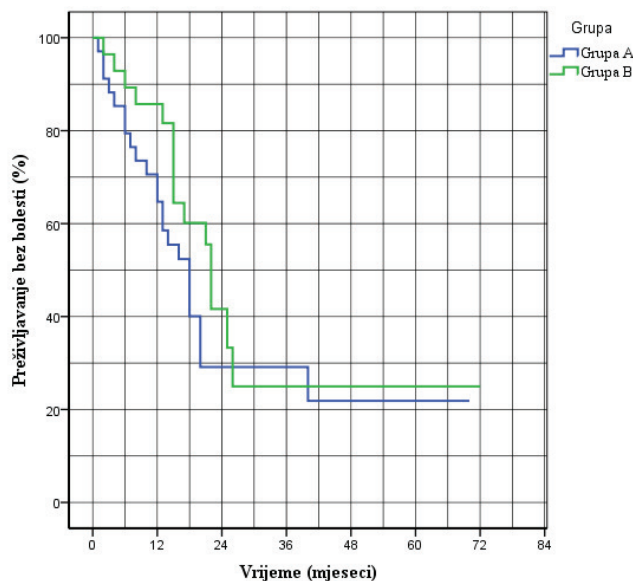
After the statistical comparisons of Kaplan-Meier curves of overall survival by Mantel-Cox test ($\chi^2 = 0.167$; $p =$

0.683), it can be concluded that there was no statistically significant difference ($p > 0.05$) between the study groups A and B when it comes to overall survival.

The median value of disease-free survival in the group A was 18 months with a standard deviation of 2.22 months, a one-year, two-year and three-year survival without disease accounted for 64.7%, 29.1% and 29.1% respectively.

In the group B, the median value of disease-free survival was 22 months with a standard deviation of 0.74 months, a one-year, two-year and three-year survival without disease accounted for 85.7%, 41.6% and 25% respectively. (Chart 2.)

Chart 2. Medial interval value without disease



After the statistical comparisons of Kaplan-Meier disease-free survival curves with Mantel-Cox test ($\chi^2 = 1.357$; $p = 0.244$), it can be concluded that there was no statistically significant difference ($p > 0.05$) between the study groups A and B when it comes to disease-free survival.

Discussion

Metastases of colorectal cancer in the liver present the most common secondary tumors of liver.¹ In the study published by Scheele and his associates, 902 patients with metastatic colorectal liver cancer without resection were monitored, out of which only 21 patients survived for three years, while there was no record of five-year survival.³

In the study published by Fong and his associates, 1,001 patients who underwent surgical removal of metastatic colorectal cancer in the liver were analysed, and five

-year survival of 37% and an average life expectancy of 42 months were recorded.⁴ The study contrasted two basic surgical treatment methods of liver metastases, and demonstrated the following results: medial survival in anatomical surgery was 39 months, while it was 46 months in metastasectomy.⁴ While the one-, three- and five-year survival rate for anatomical surgeries was 85% for one year, 53% for three years and 37% for five-year survival,⁴ in our study, the results amounted to 89.3% for one-year and 50% for three-year survival.

According to the Fong study, the results for metastasectomies amounted to 93% for one-year, 75% for three-year and 40% for the five-year survival,⁴ while our study provided the following data for metastasectomies: 85.6% for one-year and 50% for the three-year survival.

In their study from the year 2000, DeMatteo RP and associates monitored 267 patients operated in the period from 1985 to 1998. Among 119 who had undergone metastasectomies and 148 patients who had been operated anatomically, they stated the following data on the average overall survival: from 53 months in anatomical surgery versus 38 months for metastasectomies.⁵ In our study that included 65 patients, that is, 35 patients who underwent metastasectomies and 30 patients who underwent anatomical surgeries, average overall survival was 36 months for both types of surgeries. The results for one-, two- and three-year survival in cases of anatomical surgeries were 89%, 67%, 50% and in cases of metastasectomies, they were 85%, 68%, and 50%. There was no statistically significant difference in overall survival regarding the type of surgery on the liver.

In the study of 436 surgically treated patients for liver metastases of colorectal cancer, J. Scheele stated a five-year disease-free interval in 33.6% patients.³ In our study which included 65 patients, median disease-free interval was 22 months for anatomical surgery and 18 months for metastasectomies surgeries.

Conclusion

Surgery is the primary and irreplaceable method of treatment of liver metastases of colorectal cancer. Altogether, the survival test sample was 36 months. Disease-free interval with anatomic resection was 22 months, while it was 18 months with metastasectomies.

References

1. Morris EJ, Forman D, Thomas JD. Surgical management and outcomes of colorectal cancer liver metastases. *Br J Surg.* 2010; 97:1110-1118. <http://dx.doi.org/10.1002/bjs.7032> PMID:20632280.

2. Poston G. The argument for liver resection on colorectal liver metastases. *Hepato-gastroenterology*. 2001; 48: 345-356.
PMid:11379306
3. Scheele J: Anatomical and atypical liver resections. *Chirurg*. 2001;72(2):113-124 Couinaud C: *Etudes anatomiques et chirurgicales*. 11th ed. Paris: Mason, 1957.
PMCID:PMC2192393
4. Fong Y, Fortner J, Sun RL et al. Clinical score for predicting recurrence after hepatic resection for metastatic colorectal cancer, analysis of 1001 consecutive cases. *Ann Surg* 1999;230:309-21.
<http://dx.doi.org/10.1097/00000658-199909000-00004>
PMid:10493478 PMCID:PMC1420876
5. De Matteo RP, Palese C, Jarnagin WR, Sun RL, Blumgart LH, Fong Y: Anatomic segmental hepatic resection in superior to wedge resection as an oncologic operation for colorectal liver metastases *J Gastrointest Surg*. 2000;4(2):178-184
[http://dx.doi.org/10.1016/S1091-255X\(00\)80054-2](http://dx.doi.org/10.1016/S1091-255X(00)80054-2)

Hirurško liječenje metastaza kolorektalnog karcinoma u jetri

SAŽETAK

Uvod. Kolorektalni metastatski tumori jetre spadaju u najčešće sekundarne tumore jetre. Kod polovine od ukupnog broja će tokom života biti razvijene jetrene metastaze, sinhrono ili metahrono. U vrijeme postavljanja dijagnoze, kod oko 25% pacijenata sa kolorektalnim karcinomom uočeno je prisustvo sekundarnih depozita u jetri, a dodatnih 25% pacijenata će razviti metastaze unutar narednih pet godina.

Cilj rada. Cilj rada bio je dokazati da anatomske resekcije jetre predstavljaju metodu izbora pri hirurškom tretmanu kolorektalnih jetrenih metastaza u odnosu na metastazektomijske operacije.

Ispitanici i metode. Istraživanje je sprovedeno na 70 pacijenata. Kod pacijenata u prvoj grupi radila se metastazektomija koja se sastojala od odstranjenja metastaze i okolnog jetrenog parenhima ne više od 1cm tehnikom Kelly-crysis ili Ligasure aparatom. Kod bolesnika u drugoj grupi rađena je anatomska resekcija jetre prilikom koje se odstranila metastaza i pripadajući anatomski segment ili sekcija, odnosno polovica jetre u zavisnosti od broja i lokalizacije metastaza.

Rezultati. Srednja vrijednost za prvu grupu sveukupnog preživljavanja bila je 36 mjeseci sa standardnom devijacijom 4,8 mjeseca. Srednja vrijednost sveukupnog preživljavanja kod pacijenata druge grupe bila je 36 mjeseci sa standardnom devijacijom 2,6 mjeseci. Srednja vrijednost preživljavanja bez bolesti u prvoj grupi bila je 18 mjeseci sa standardnom devijacijom 2,22 mjeseca. U drugoj grupi, srednja vrijednost preživljavanja bez bolesti bila je 22 mjeseca sa standardnom devijacijom 0,74 mjeseca.

Zaključak. Sveukupno preživljavanje kod obe vrste operacija bilo je identično i medijan sveukupnog preživljavanja iznosio je 36 mjeseci. Interval bez bolesti kod anatomskih resekcija iznosio je 22 mjeseca, dok je kod metastazektomijskih operacija bio 18 mjeseci. Iz svega gore navedenog može se zaključiti da hirurgija predstavlja osnovnu i nezamjenjivu metodu liječenja jetrenih metastaza karcinoma debelog crijeva.

Ključne riječi: jetra, metastaza, metastazektomija, anatomska resekcija.