



Disruptive Technologies in Cardiac Surgery and Interventional Cardiology

Jacob Bergsland^{1,2,3}

Abstract

The last several decades have witnessed a huge expansion of surgical and interventional treatment of cardiac disease. Axel Cappelen from Oslo, Norway was one of the first to operate on the heart, something that had until then, been considered foolish and without chance of success.¹ Cappelen dared to operate on the heart in spite of Billroth's stark warning against such "unwise" attempts as he ligated a bleeding coronary artery caused by a stabbing injury. Most of the innovation in recent years has been within the interventional cardiology domain in contrast to the first 7 decades of the 20th century, when surgeons dominated. Cardiac surgeons have developed less invasive procedures, although the most common surgical incision is based on the time-honoured and large median sternotomy incision. Many surgeons continue to prefer the concept of "Grosse Chirurgen, Grosse Schnitte" and have stayed away from minimisation and continue to use direct vision, usually augmented by magnification glasses, median sternotomy and cardiopulmonary bypass (CPB). However, new technology has made the need for CPB less important². In this article a selection of recently developed devices for cardiac intervention will be described.

Key words: mitral valve; aortic valve; valve surgery; valve intervention.

- (1) Director for Science and Education, BH Heart Centre Tuzla, Tuzla, Bosnia and Herzegovina.
- (2) Cardiac Surgeon and Researcher, Intervention Centre, Oslo University Hospital, Oslo, Norway.
- (3) Medical Director, Cardiomech AS Trondheim, Drøbak, Norway.

Correspondence:

JACOB BERGSLAND
E: jacobbergsland622@gmail.com
M: +47 930 31 292

ARTICLE INFO

Received: 22 January 2020
Revision received: 10 February 2020
Accepted: 12 February 2020

Introduction

The development of cardiac interventional care has required technological innovation and dedicated and qualified personnel. It was more than 100 years ago that the first coronary bypass procedure was performed on research animals by the Nobel Laureate Alexis Carrell, but it required the development of cardiac catheterisation to diagnose the extent and localisation of coronary lesions and the CPB-machine to operate on a motionless heart. The heart-lung machine made coronary bypass feasible, but again became unnecessary with the development of off the pump bypass surgery (OPCAB). New technology made OPCAB feasible and safe.³⁻⁵

Interestingly, many of the common cardiac con-

ditions affecting the heart valves had surgical solutions before CPB was developed and some of these methods have now been revived using catheter-based techniques. Mitral stenosis, one of the most common cardiac conditions before the time of antibiotics and treatment of streptococcal infections, could be effectively relieved with mitral commissurotomy performed with a left thoracotomy and access to the mitral valve through the left atrial appendix. The surgeon would use his finger or an instrument to dilate the stenosed valve, thereby relieving disabling congestive heart failure (Figure 1).⁶ In the Western World such closed procedures were mostly replaced by open commissurotomy on CPB and an arrested heart to decrease the risk of embolisation. Later, cath-

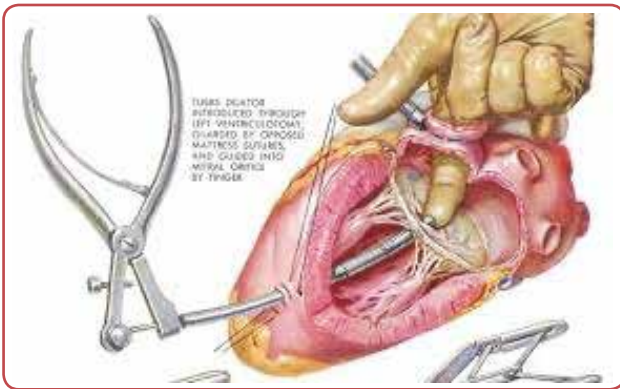


Figure 1. Mitral commissurotomy performed surgically on the beating heart

eter-based balloon-dilatation, using a transseptal catheter technique, has become a successful method for treating mitral stenosis (Figure 2).⁷ In 2003 it was reported that a third of patients with mitral stenosis were treated with balloon dilatation in Europe.⁸ Closed, operative dilatation for aortic stenosis without CPB was performed through a transapical technique and a surgical instrument was used to open up the fused aortic leaflets. This procedure was less successful than dilatation of the mitral valve as demonstrated by the experience with aortic balloon valvuloplasty.⁹

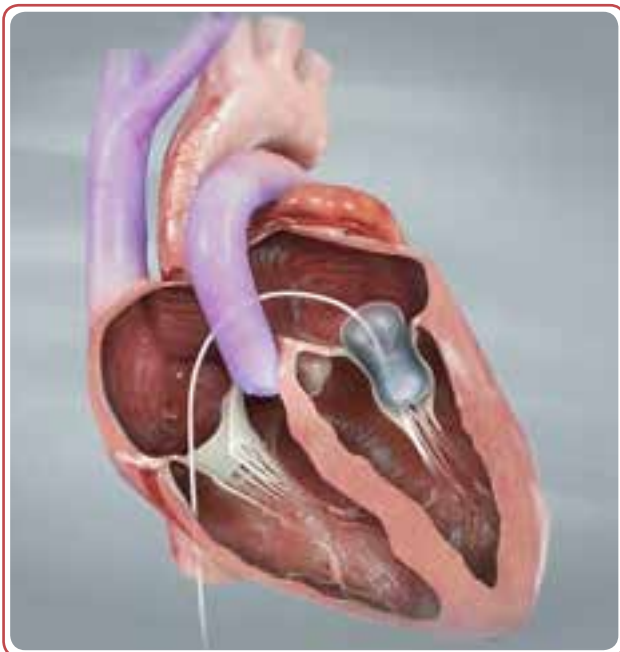


Figure 2. Balloon commissurotomy is performed through the femoral vein and the atrial septum

For many years valve replacement was the most common invasive treatment for patients with disease of the valves, regardless of whether the pathology caused stenosis, insufficiency or a combination of both. Both tissue and mechanical valves performed well and selection of type depended

on age, co-morbidities, surgeon and patient preferences or other factors.¹⁰ The pulmonary and tricuspid valves were treated surgically and to an extent with catheter-based techniques. Focus of development, science and practice in the early, mainly surgical, era was valve-replacement and a number of mechanical valves were developed, including Starr-Edwards, Björk-Shiley, Medtronic Hall and others. These mechanical devices were made of artificial material and required life-long anticoagulation. Alternative devices were made of a combination of biologic and synthetic tissues where the leaflets were biological and less thrombogenic. Anticoagulation could therefore be avoided, which is a major benefit for quality of life. The main disadvantage was the shorter durability of biological valves, making reoperation a common scenario especially for younger patients and pre-menopausal women.

While stenotic lesions of the mitral and aortic valves could be treated with dilatation, regurgitation was a more complex issue. While most surgeons elected to replace the leaking valves, it became increasingly evident that the degenerative valve pathology, especially for the mitral valve, could be repaired, preventing the adverse effects of a prosthesis. Surgical mitral valve repair became, and still is, an excellent choice. Techniques for mitral valve repair were developed by a life-long dedication by the French surgeon Alain Carpentier and others.^{11,12} His ground-breaking work resulted in further understanding of the mitral valve's function and pathology and the development of the techniques to repair the valve with excellent results and low rates of reoperation.¹³ Aortic insufficiency has been more difficult to repair and surgical therapy has mainly been the valve replacement.

Until the 1970s, cardiology interventionists were mainly involved in diagnosis of cardiac conditions, while surgery was a dominant invasive non-medical therapy. This changed after Andreas Grüntzig's disruptive approach to coronary artery disease when he started performing percutaneous balloon angioplasty.^{14,15} After stents were added to the procedures, it has become safer and is now performed much more commonly than the coronary artery bypass grafting. To most cardiac specialists it seemed unlikely that catheter-based therapy could be a major factor in treatment of valvular conditions, except for dilatation of the mitral¹⁶ and aortic valves.¹⁷

The Present State and Emerging Technology

The development of catheter-based alternatives to surgery for stenotic lesions in coronary arteries and aortic and mitral valves led to further pursuit of new solutions by physicians, surgeons and engineers. The med tech industrial giants and numerous upstart companies saw a huge potential in developing less invasive therapies, mainly based on catheter interventions. In other surgical specialties, like gastrointestinal surgery, minimally invasive techniques have penetrated the Western world and even the remote and poor countries,¹⁸ but unfortunately thoracoscopic and robotic operations for cardiac disease has not gained general acceptance, in spite of clear demonstration of clinical feasibility and excellent results.¹⁹ The majority of surgeons does not possess required skills or acceptance of the paradigm shifts necessary for minimal invasive approaches. However, similar to what occurred regarding valve dilatations, many new ideas for interventional therapy came from surgeons who were used to seeing cardiac pathology "in real life". When surgeons, cardiologists and engineers worked together, interventionists with imaging- and catheter-expertise could perform intracardiac procedures with good results. In the following a selection of the new devices and methods available and under development will be described. Due to space constraints, a complete review will not be possible.

Aortic valve

Dilatation of the aortic valve to relieve stenosis was attempted in the pre-cardiopulmonary bypass using a transapical approach where a surgical dilator instrument was introduced antegrade through the aortic valve. When CPB became available, aortic valves were mostly replaced using CPB and on an arrested heart. Balloon dilatation through a retrograde approach from the femoral artery continued to be a valuable technique in some cases, but the procedure either did not relieve stenosis adequately or resulted in aortic insufficiency.²⁰ Implantation of a prosthesis using a transcatheter approach was developed by Cribier and others, who described the procedure and initiated it clinically in Rouen, France.²¹ Within a few years several implantable valves were on the market, the most common were the Sapien™, Edwards Inc., USA and Corevalve™ Medtronic Inc.,

USA. Sapien™ is made of bovine tissue mounted on a cobalt-chromium metal frame and is balloon-expandable (Figure 3), while the Corevalve™ (presently named Evolut™) is made of porcine pericardium mounted on self-expandable nitinol (Figure 4).²² Extensive, controlled, clinical studies have been undertaken demonstrating benefits compared to surgery of this transcatheter approach first in high- then in intermediate- and finally in low-risk patients.²³ In several markets transcatheter aortic valve implantation (TAVI) is now more common than surgical valve implantation. The high cost of the device and delivery catheters has been a limitation to the implementation of the technique in less prosperous markets. Several new devices are in different phases of development and will probably eventually result in a more affordable price-structure.

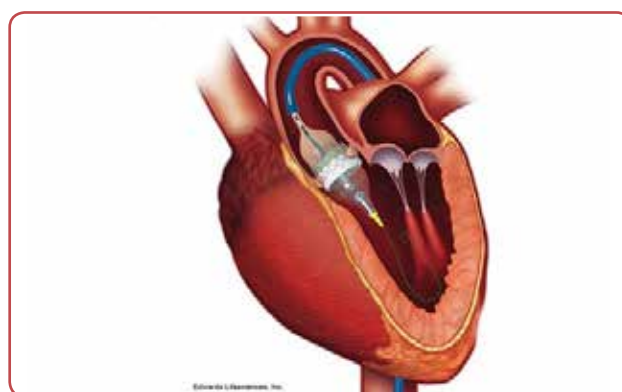


Figure 3. Sapien™ aortic prosthesis placed with catheterisation of the femoral artery and balloon dilatation

Mitral Valve

The mitral valve is anatomically more complex than the aortic and mitral stenosis, especially

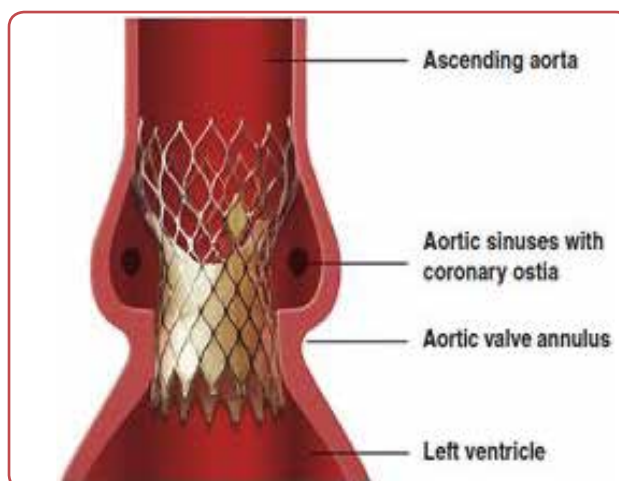


Figure 4. Corevalve™ self-expandable aortic prosthesis placed transfemorally

when less calcified, can usually be successfully treated with balloon dilatation.²⁴ Mitral regurgitation (MR) is more difficult to treat as it has a number of different aetiologies and variable anatomy, but development has accelerated in spite of technological challenges, strict regulation and financial challenges.²⁵

There is much variability among regurgitant mitral valves; the two main categories being degenerative (DMR) and functional (FMR) mitral regurgitation (MR).²⁶

DMR is MR caused by a primary defect in the mitral valve itself, while FMR is caused by conditions affecting the left ventricle (LV), causing dilation of the mitral annulus and subsequent (secondary) MR. DMR can in many cases be treated surgically with valve repair and if the repair is performed by an experienced team, outcomes are excellent. For FMR the prognosis is worse and mitral repair or replacement, in spite of symptomatic improvement, do not improve long-term survival unless the LV function recovers.

For both DMR and FMR interventional therapies are being developed to decrease invasiveness and make treatment available for larger groups of patients. A few of the devices and methods in various phases of development are presented here.

a) Mitraclip™, Abbott Inc., USA (Figure 5) was designed to reproduce a surgical procedure invented by Alfieri.²⁷ With the Alfieri method, the anterior and posterior leaflets of the mitral

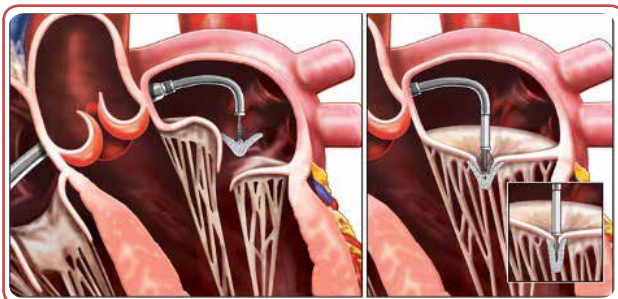


Figure 5. Mitraclip™ transseptal device for mitral valve repair

valve are sutured together, creating a double outlet valve where the two leaflets support each other. Mitraclip can produce the same anatomical result as the Alfieri procedure by fixing the two leaflets together with a patent-

ed clip deployed with a catheter approach.²⁸ The catheter is introduced through the femoral vein and trans-septally into the left atrium. An animation can be seen on YouTube (link: <https://www.youtube.com/watch?v=4-yT-POEaZzg>). Mitraclip can be used in DMR by fixing a prolapsing or flail leaflet to the opposite leaflet, thereby eliminating or decreasing MR. The device can also be used in FMR since it improves coaptation of the leaflets, thereby reducing MR. This effect on patients with FMR has been demonstrated in a well conducted randomised study in the US (COAPT-study),²⁹ which demonstrated lower mortality, less heart failure symptoms and improved LV function compared to the optimal medical treatment.

b) Implantation of annuloplasty ring. Cardio-band™, Edwards Lifesciences, USA, is also used through a transseptal approach.³⁰ The annuloplasty ring is sutured in place in the mitral valve annulus, using a sophisticated anchoring system. The procedure is explained by this animation (<https://www.youtube.com/watch?v=zVIAOs3Ifsc>)

This ring is inspired from the surgical annuloplasty procedure and intended to reduce the size of the mitral annulus thereby improving coaptation of the leaflets.

c) Implantation of new mitral chords. Several companies are working on devices that can repair the mitral valve by the placement of artificial chordae tendinae. Such procedures are based on concepts from surgical repair. MR caused by ruptured or degenerated mitral chords can be repaired by placing artificial

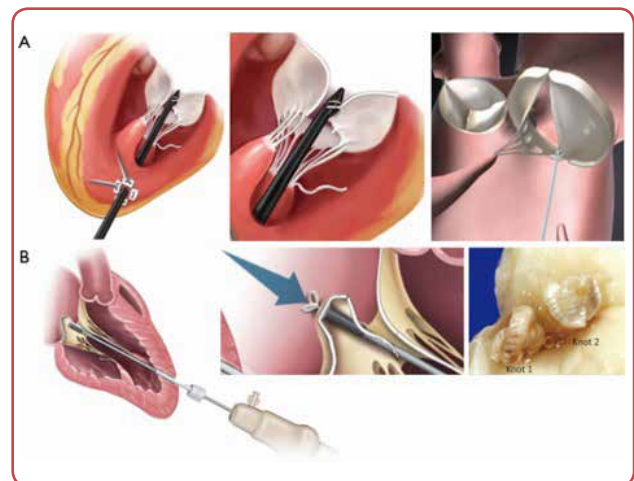


Figure 6. A. NeoChord's DS 1000™ device for transapical insertion of artificial chords B. Harpoon™ device for transapical insertion of artificial chords

chords between the prolapsing leaflet and the papillary muscles, thereby increasing coaptation of the anterior and posterior leaflets.

Different concepts for placing such “neo-chords” include transapical approaches, where a small thoracotomy is used to place chords between the prolapsing leaflet and the wall of the LV. The length of the chords can be adjusted under ultrasonic imaging until MR is eliminated. DS1000™, NeoChord Inc., USA (Figure 6A) and Harpoon™ Edwards Lifesciences Inc, USA (Figure 6B) are devices under clinical investigations for trans-apical chordal implantation. DS 1000™ is approved in Europe and several reports have been published demonstrating good results.^{31, 32} Transfemoral chordal implantation has been developed by Cardiomech AS, Trondheim, Norway, Cardiomech MVRSTM³³ (Figure 7). The device is still in preclinical trials and not available for clinical use. Several other companies are in the process of developing transfemoral devices.

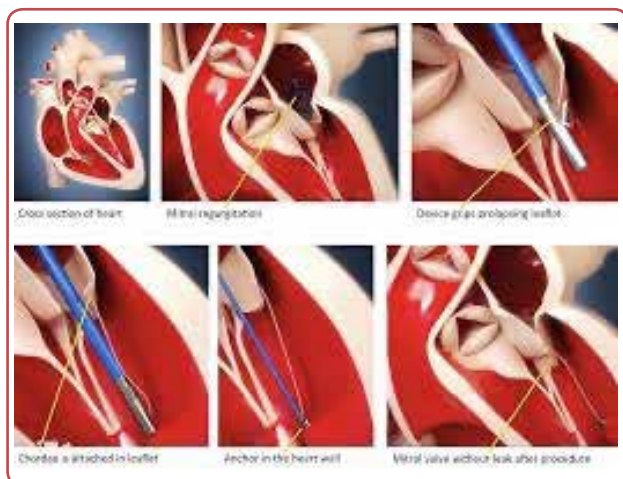


Figure 7. Cardiomech's device for transseptal implantation of artificial chords

d) Surgical mitral valve replacement gives good long-term result for patients with MR, but can contribute to the obstruction of the aortic outlet, but this can usually be prevented by careful planning.³⁴ Several transapical valves have been designed and implemented including Tendyne™, Abbott Inc., USA (Figure 8)³⁵ which has recently received the CE mark after successful human studies.³⁶ Tiara™, Neovasc Inc., Canada³⁷ and Intrepid™ Medtronic, USA³⁸ are transcatheter mitral prosthesis in clinical trials.

Pulmonary Valve

Balloon dilatation has been used for many years for treatment of congenital pulmonary steno-

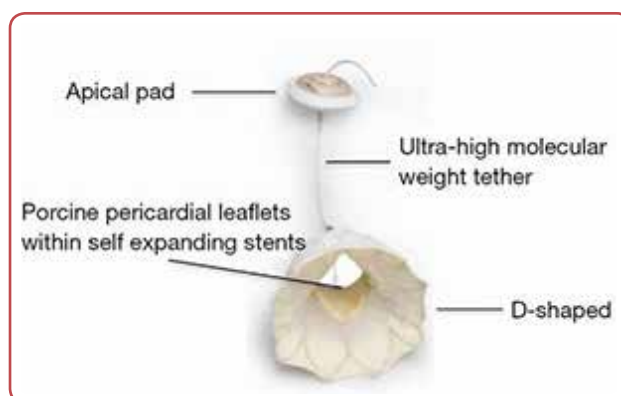


Figure 8. Tendyne™ Mitral valve prosthesis for transapical implantation. Figure shows valve and button for securing position

sis.³⁹ The Melody™ Medtronic, USA is a transcatheter valve designed for the treatment of leaking pulmonary valves (Figure 9), mainly used after previous surgery for congenital heart disease.⁴⁰

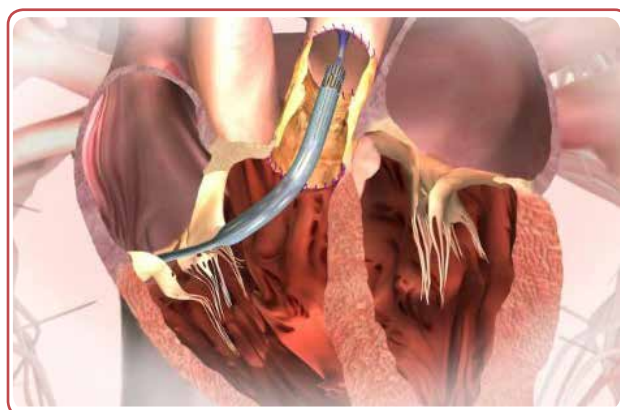

Figure 9. Melody™ Implantation of Melody valve through the right ventricle and pulmonary artery

Tricuspid valve

Tricuspid valve disease frequently occurs secondarily to other valvular disease, which can cause right ventricular (RV) dilation and tricuspid regurgitation (TR). Surgical repair of such TR at the same time as the primary valve operation improves long- and short-term outcomes.⁴¹ For patients who have high grade primary TR or TR after a previous valve operation, reoperation may be necessary. Alternatively, a transcatheter repair may in the foreseeable future be performed through a femoral or jugular venous approach.⁴² Patients with combined disease of mitral and tricuspid valves live shorter than those with only mitral dysfunction. Several devices, some adapted from mitral applications can be used in the tricuspid area.⁴³

Discussion

Cardiovascular disease remains the most common cause of death and disability worldwide. Surgical and interventional therapy save lives and improves quality of life for several hundred thousand patients every year. Classic open surgical operations were for decades dominating such therapy with coronary bypass and valve replacements being the most common procedures. The development of catheter-based therapy for coronary stenosis has led to a paradigm shift. CABG has become relatively less common while the use of acute and elective percutaneous coronary interventions has increased dramatically. The biggest benefit is seen in patients with acute myocardial infarction.

Interventional therapy for valvular disease is now increasing rapidly. Development of new devices are complex and costly and requires long time for regulatory approval.⁴⁴ Use of TAVI has increased rapidly after regulatory approval of Sapien™ in 2012.⁴⁴ A number of other TAVI valves are now on the market or under development. The development of transcatheter devices for mitral valve repair has been slower, but the Mitraclip™ and NeoChord DS 1000 are already on the market and are expected to be followed by a number of other devices. Similarly, start up and strategic medical device companies are actively pursuing new and innovative solutions.

Conclusion

In conclusion, the trend towards image-guided procedures performed with minimally invasive surgical and interventional therapies is rapidly changing the way patients with cardiovascular disease are treated. The increasing number of devices and competition in the strategic device industry will eventually bring down the costs. The availability of less invasive procedures will make effective therapies available for new patient groups, some of them not eligible for higher risk surgical operations. At the same time, shorter hospital length of stay and lower rates of adverse events will decrease cost to the individual patients and for the society at large.

Conflict of interest

None.

Acknowledgements

The author is one of the founders and the medical director of Cardiomech, AS, Trondheim, Norway.

References

1. Soreide K, Soreide JA, Axel H, Cappelen, MD (1858-1919): first suture of a myocardial laceration from a cardiac stab wound. *J Trauma* 2006;60(3):653-4.
2. Mujanovic E, Nurkic M, Caluk J, Terzic I, Kabil E, Bergsland J. The effect of combined clopidogrel and aspirin therapy after off-pump coronary surgery. *Innovations* 2009;4:265-8.
3. Bergsland J, D'Ancona G, Karamanoukian H, Ricci M, Schmid S, Salerno TA. Technical tips and pitfalls in OPCAB surgery: the buffalo experience. *Heart Surg Forum* 2000;3(3):189-93.
4. Bergsland J, Hasnain S, Lajos TZ, Salerno TA. Elimination of cardiopulmonary bypass: a prime goal in reoperative coronary artery bypass surgery. *Eur J Cardiothorac Surg* 1998;14(1):59-62; discussion 63.
5. Ricci M, Karamanoukian HL, Salerno TA, Dancona G, Bergsland J. Role of coronary graft flow measurement during reoperations for early graft failure after off-pump coronary revascularization. *J Card Surg* 1999;14(5):342-7.
6. Heger JJ, Wann LS, Weyman AE, Dillon JC, Feigenbaum H. Long-term changes in mitral valve area after successful mitral commissurotomy. *Circulation* 1979;59(3):443-8.
7. Khan MN. The relief of mitral stenosis. An historic step in cardiac surgery. *Tex Heart Inst J* 1996;23(4):258-65; discussion 65-6.
8. Iung B, Baron G, Butchart EG, Delahaye F, Gohlke-Barwolf C, Levang OW, et al. A prospective survey of patients with valvular heart disease in Europe: The Euro Heart Survey on Valvular Heart Disease. *Eur Heart J* 2003;24(13):1231-43.
9. Jabbour RJ, Dick R, Walton AS. Aortic balloon valvuloplasty--review and case series. *Heart Lung Circ* 2008;17 Suppl 4:S73-81.
10. Baldwin ACW, Tolis G, Jr. Tissue valve degeneration and mechanical valve failure. *Curr Treat Options Cardiovasc Med* 2019;21(7):33. doi: 10.1007/s11936-019-0735-2.
11. Acar C, Vahanian A, Jebara VA, Fabiani JN, Deloche A, Acar J, et al. Mitral valve repair for anterior leaflet disruption after percutaneous mitral dilation. *J Thorac Cardiovasc Surg* 1991;102(3):468-9.
12. Jouan J, Berrebi A, Chauvaud S, Menasche P, Carpentier A, Fabiani JN. Mitral valve reconstruction in Bar-

- low disease: long-term echographic results and implications for surgical management. *J Thorac Cardiovasc Surg* 2012;143(4 Suppl):S17-20.
13. el Asmar B, Perier P, Couetil JP, Carpentier A. Failures in reconstructive mitral valve surgery. *J Med Liban* 1991;39(1):7-11.
 14. Gruntzig A, Hirzel H, Goebel N, Gattiker R, Turina M, Myler R, et al. [Percutaneous transluminal dilatation of chronic coronary stenoses. First experiences]. *Schweiz Med Wochenschr* 1978;108(44):1721-3. German.
 15. Barton M, Gruntzig J, Husmann M, Rosch J. Balloon Angioplasty - The Legacy of Andreas Gruntzig, M.D. (1939-1985). *Front Cardiovasc Med* 2014 Dec 29;1:15. doi: 10.3389/fcvm.2014.00015.
 16. Silin VA, Sukhov VK. [Percutaneous endovascular catheter balloon dilatation of mitral and aortic valve stenosis]. *Vestn Khir Im I I Grek* 1990;144(4):8-12. Russian.
 17. Di Mario C, Beatt KJ, de Feyter P, van den Brand M, Essed CE, Serruys PW. Percutaneous aortic balloon dilatation for calcific aortic stenosis in elderly patients: immediate haemodynamic results and short-term follow up. *Br Heart J* 1987;58(6):644-52.
 18. Lombardo S, Rosenberg JS, Kim J, Erdene S, Sergelen O, Nellerme J, et al. Cost and outcomes of open versus laparoscopic cholecystectomy in Mongolia. *J Surg Res* 2018;229:186-91.
 19. Pfannmüller B, Seeburger J, Misfeld M, Borger MA, Garbade J, Mohr FW. Minimally invasive mitral valve repair for anterior leaflet prolapse. *J Thorac Cardiovasc Surg* 2013;146(1):109-13.
 20. Letac B, Cribier A, Berland J. [Percutaneous valvuloplasty using a balloon catheter in acquired mitral and aortic stenosis in adults]. *Schweiz Med Wochenschr* 1988;118(46):1673-80. French.
 21. Cribier A. [Catheter-assisted implantation of aortic valves in degenerative aortic stenosis]. *Bull Acad Natl Med* 2012;196(3):659-61. French.
 22. Nombela-Franco L, Ruel M, Radhakrishnan S, Webb JG, Hansen M, Labinaz M, et al. Comparison of hemodynamic performance of self-expandable CoreValve versus balloon-expandable Edwards SAPIEN aortic valves inserted by catheter for aortic stenosis. *Am J Cardiol* 2013;111(7):1026-33.
 23. Søndergaard L, Steinbrüchel DA, Ihlemann N, Nissen H, Kjeldsen BJ, Petursson P, et al. Two-year outcomes in patients with severe aortic valve stenosis randomized to transcatheter versus surgical aortic valve replacement: the All-Comers Nordic Aortic Valve Intervention Randomized Clinical Trial. *Circ Cardiovasc Interv* 2016 Jun;9(6). pii: e003665. doi: 10.1161/CIRCINTERVENTIONS.115.003665.
 24. Reid CL, Rahimtoola SH. The role of echocardiography/Doppler in catheter balloon treatment of adults with aortic and mitral stenosis. *Circulation* 1991;84(3 Suppl):I240-9.
 25. Bergsland J, Elle OJ, Fosse E. Barriers to medical device innovation. *Med Devices (Auckl)* 2014;7:205-9.
 26. Sideris K, Boehm J, Voss B, Guenther T, Lange RS, Guenzinger R. Functional and degenerative mitral regurgitation: one ring fits all? *Thorac Cardiovasc Surg* 2019 Sep 23. doi: 10.1055/s-0039-1696989.
 27. Maisano F, Torracca L, Oppizzi M, Stefano PL, D'Addario G, La Canna G, et al. The edge-to-edge technique: a simplified method to correct mitral insufficiency. *Eur J Cardiothorac Surg* 1998;13(3):240-5; discussion 5-6.
 28. Maisano F, Buzzatti N, Taramasso M, Alfieri O. Mitral transcatheter technologies. *Rambam Maimonides Med J* 2013 Jul 25;4(3):e0015. doi: 10.5041/RMMJ.10115.
 29. Mack MJ, Abraham WT, Lindenfeld J, Bolling SF, Feldman TE, Grayburn PA, et al. Cardiovascular outcomes assessment of the MitraClip in patients with heart failure and secondary mitral regurgitation: design and rationale of the COAPT trial. *Am Heart J* 2018;205:1-11.
 30. Ferrero Guadagnoli A, De Carlo C, Maisano F, Ho E, Saccocci M, Cuevas O, et al. Cardioband system as a treatment for functional mitral regurgitation. *Expert Rev Med Devices* 2018;15(6):415-21.
 31. Colli A, Adams D, Fiocco A, Pradegan N, Longinotti L, Nadali M, et al. Transapical NeoChord mitral valve repair. *Ann Cardiothorac Surg* 2018;7(6):812-20.
 32. Colli A, Manzan E, Aidielis A, Rucinskas K, Bizzotto E, Besola L, et al. An early European experience with transapical off-pump mitral valve repair with NeoChord implantation. *Eur J Cardiothorac Surg* 2018;54(3):460-6.
 33. Bergsland J, Mirtaheri P, Hiorth N, Fosse E. Review of the endovascular approach to mitral valve disease. *Minim Invasive Ther Allied Technol* 2015;24(5):282-8.
 34. Dahle G, Rein KA, Fiane AE. Single centre experience with transapical transcatheter mitral valve implantation. *Interact Cardiovasc Thorac Surg* 2017;25(2):177-84.
 35. Niikura H, Gossl M, Sorajja P. Transcatheter mitral valve replacement with Tendyne. *Interv Cardiol Clin* 2019;8(3):295-300.
 36. Quarto C, Davies S, Duncan A, Lindsay A, Lutter G, Lozonschi L, et al. Transcatheter mitral valve implantation: 30-day outcome of first-in-man experience with an apically tethered device. *Innovations (Phila)* 2016;11(3):174-8.
 37. Cheung A, Webb J, Schaefer U, Moss R, Deuschl FG, Conradi L, et al. Transcatheter mitral valve replacement in patients with previous aortic valve replacement. *Circ Cardiovasc Interv* 2018;11(10):e006412.
 38. McCarthy PM, Kislitsina ON, Malaisrie SC, Davidson CJ. Transcatheter mitral valve replacement with Intrepid. *Interv Cardiol Clin* 2019;8(3):287-94.
 39. Lanjewar C, Phadke M, Singh A, Sabnis G, Jare M, Kerkar P. Percutaneous balloon valvuloplasty with Inoue balloon catheter technique for pulmonary valve stenosis in adolescents and adults. *Indian Heart J* 2017;69(2):176-81.
 40. Markham R, Challa A, Kyranis S, Nicolae M, Murdoch D, Savage M, et al. Outcomes following melody transcatheter pulmonary valve implantation for right ventricular outflow tract dysfunction in repaired congenital heart disease: first reported Australian single centre experience. *Heart Lung Circ* 2017;26(10):1085-93.
 41. Cao JY, Wales KM, Zhao DF, Seco M, Celermajer DS, Bannon PG. Repair of less than severe tricuspid regurgitation during left-sided valve surgery: a meta-analysis. *Ann Thorac Surg* 2020;109(3):950-8.
 42. Karam N, Braun D, Mehr M, Orban M, Stocker TJ, Deseive S, et al. Impact of transcatheter tricuspid valve repair for severe tricuspid regurgitation on kidney and liver function. *JACC Cardiovasc Interv* 2019;12(15):1413-20.
 43. Williams AM, Bolling SF, Latib A. The five Ws of transcatheter tricuspid valve repair: Who, What, When, Where, and Why. *EuroIntervention* 2019;15(10):841-5.
 44. Kaplan AV, Williams DO. Medical device regulatory landscape: the imperative of finding balance. *Circ Cardiovasc Interv* 2012;5(1):2-5.